

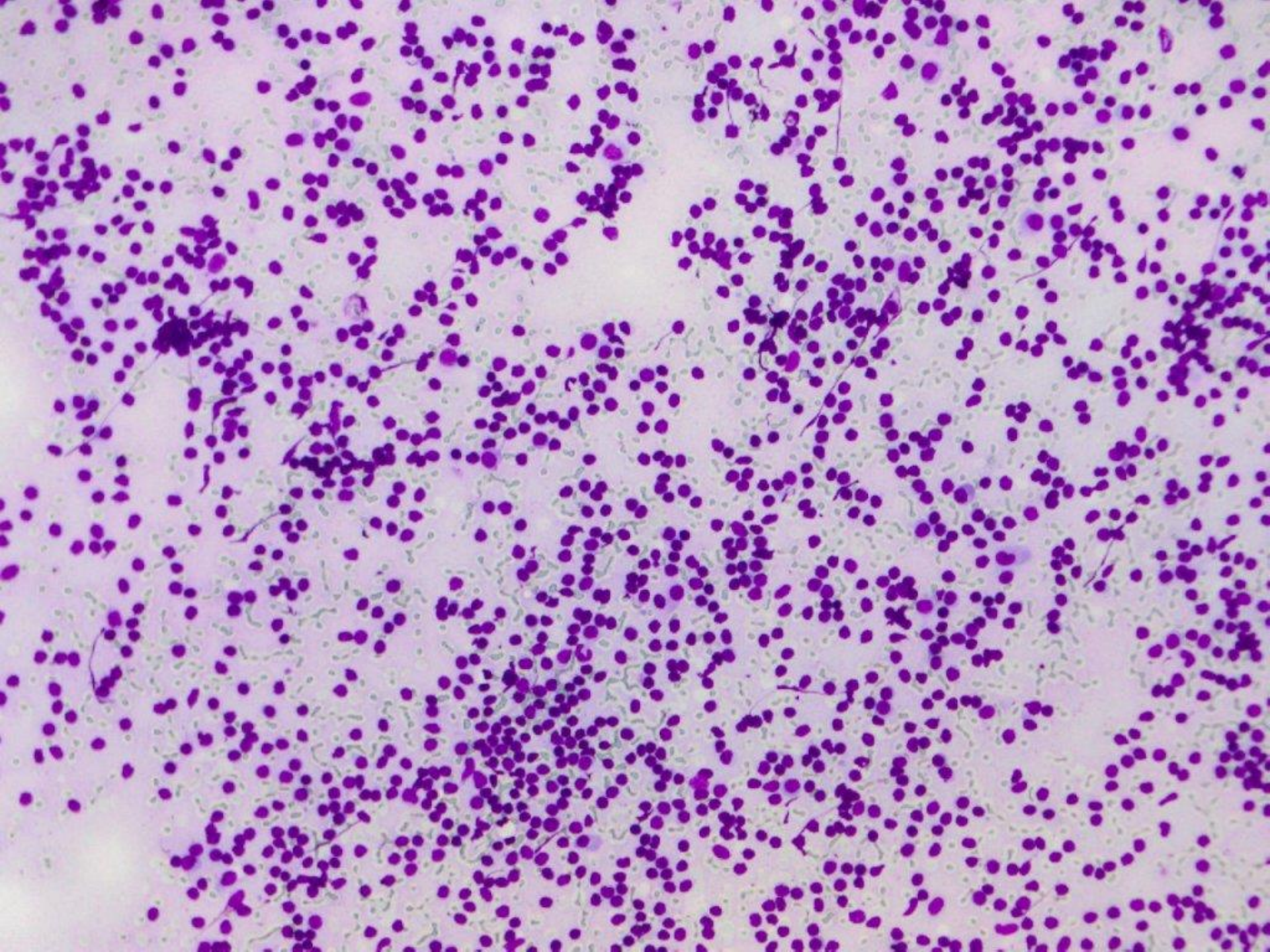
Oral Histopathology

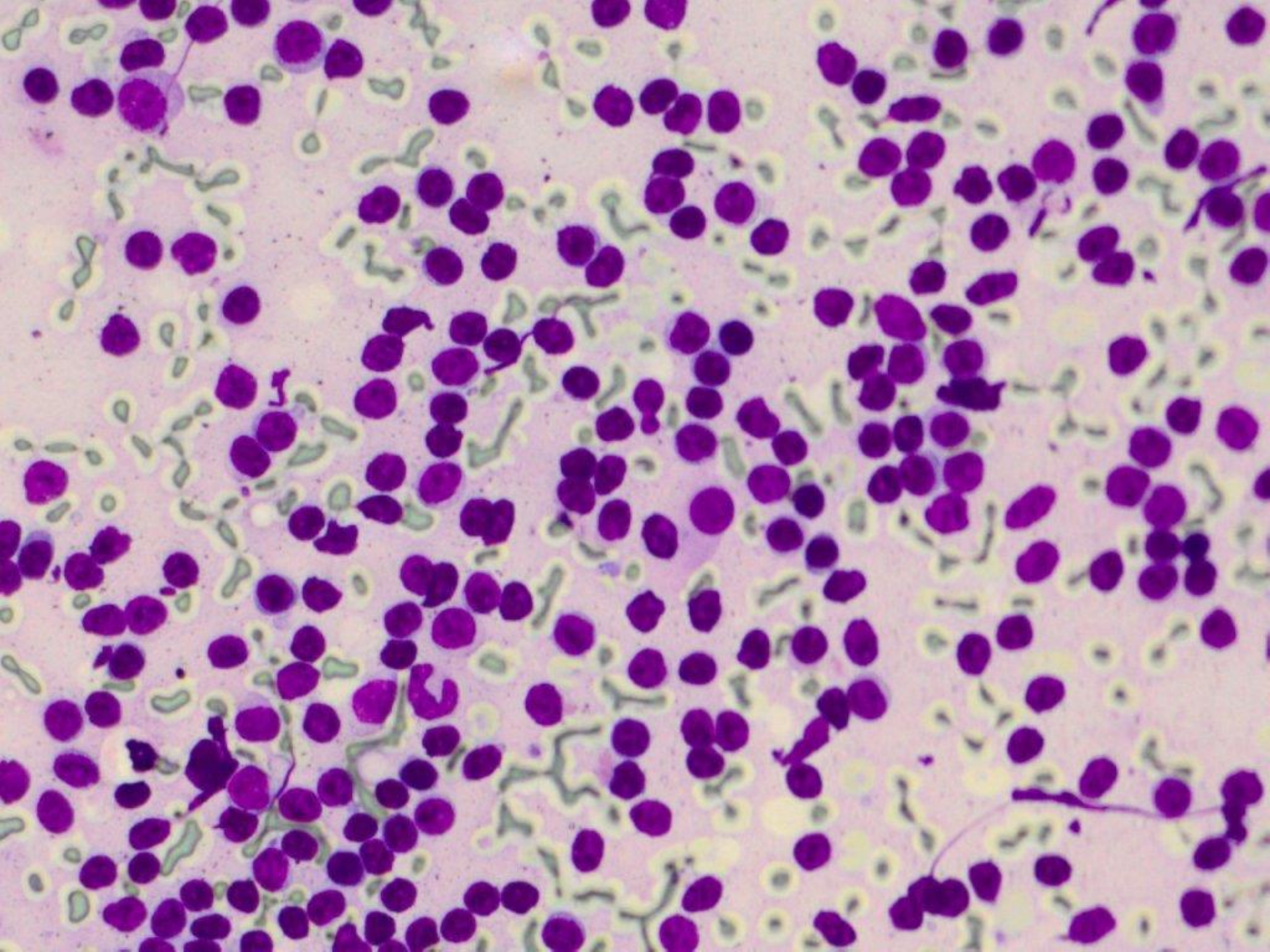
Series 10

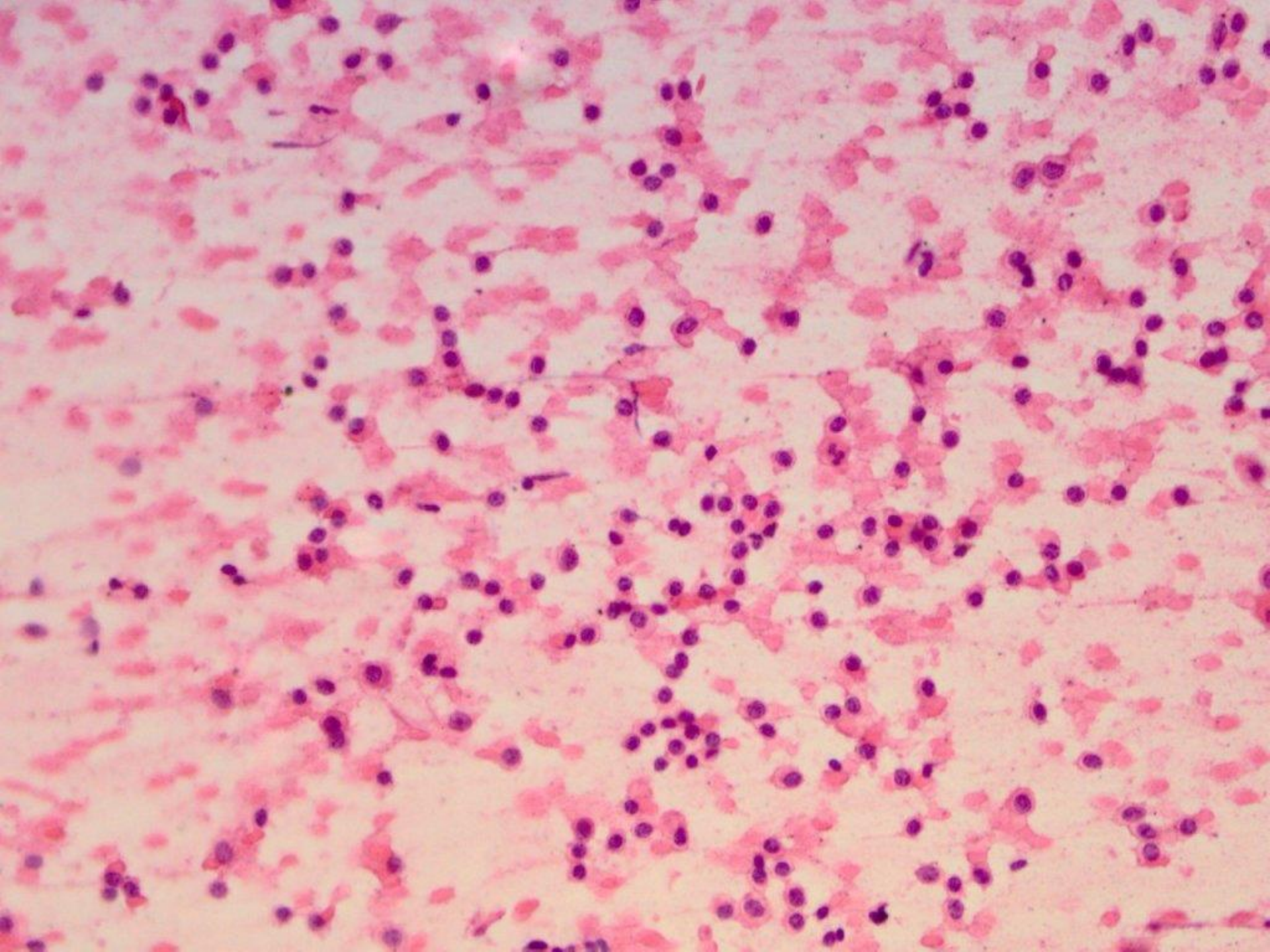
DAVID E. KLINGMAN, DMD

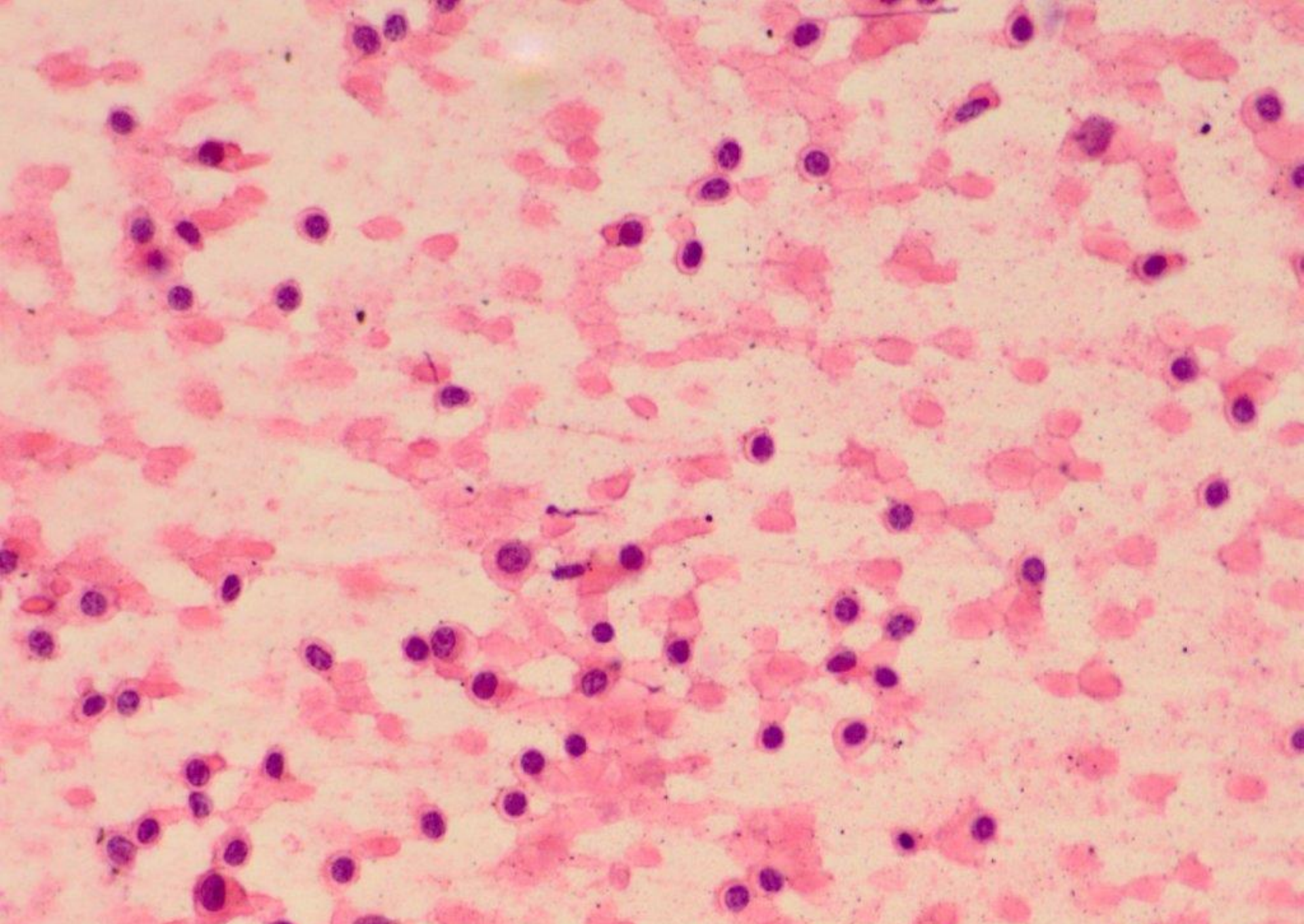
Diplomate, American Board of Oral and Maxillofacial Pathology

Diplomate, American Board of General Dentistry

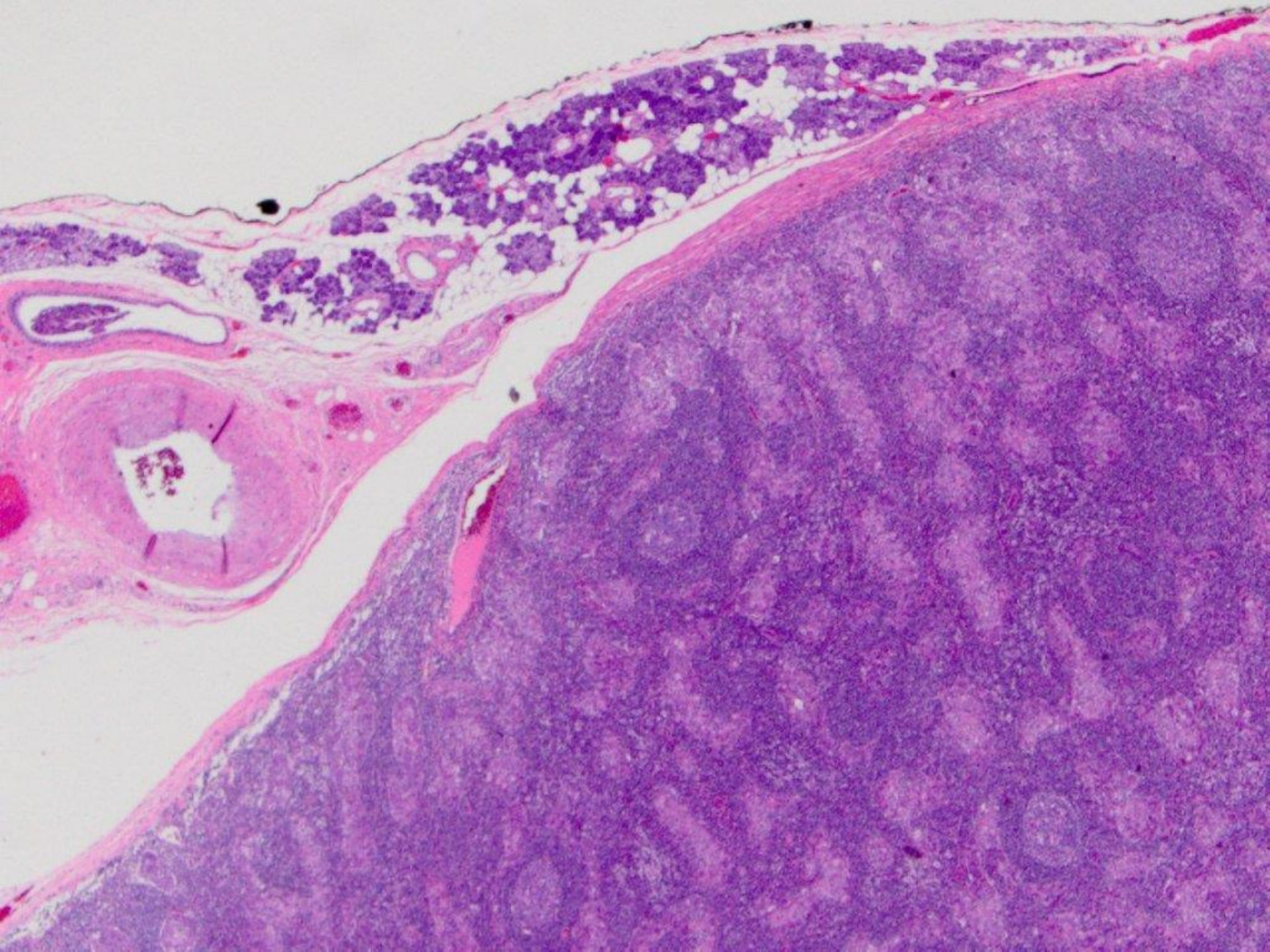


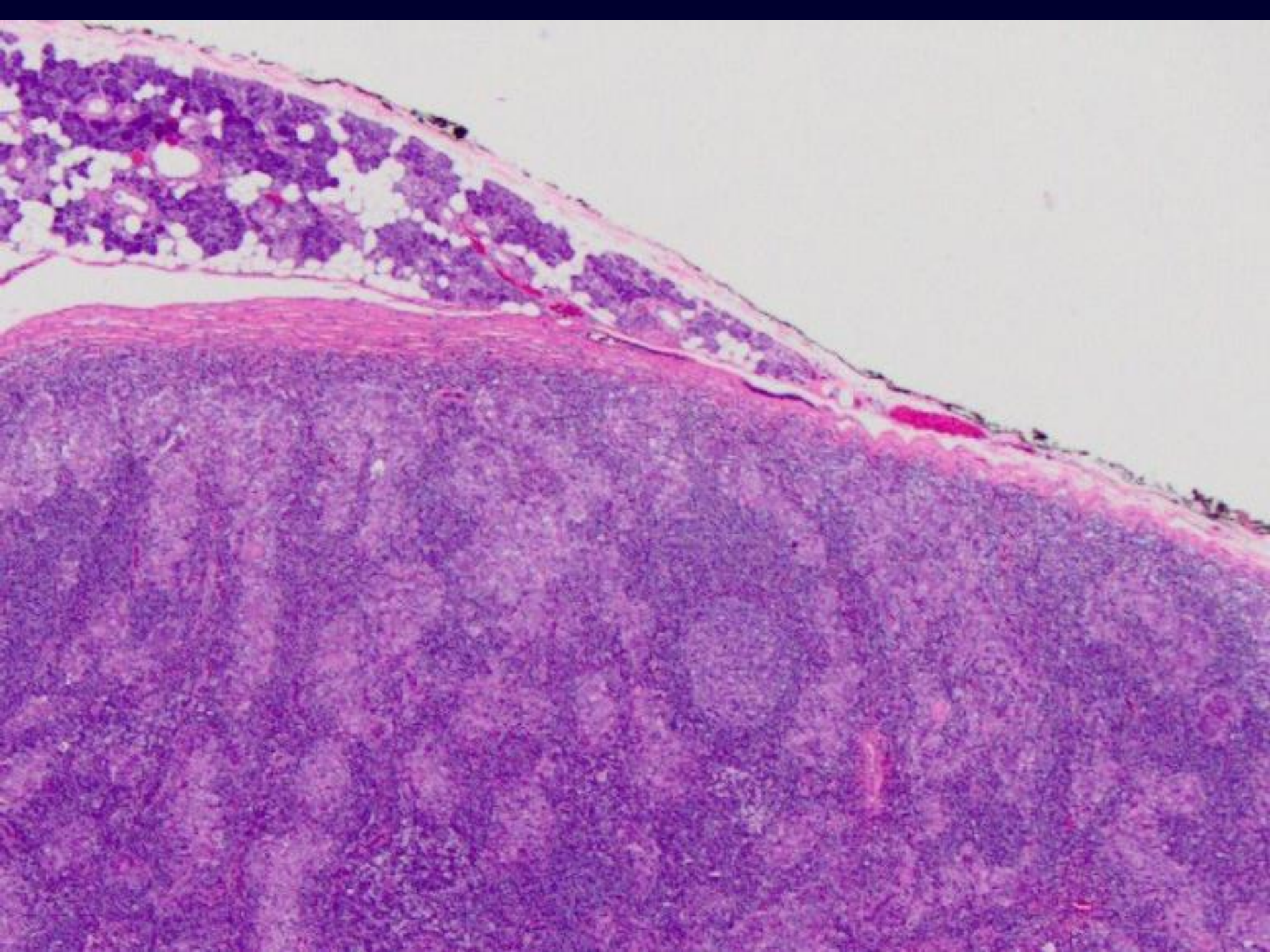


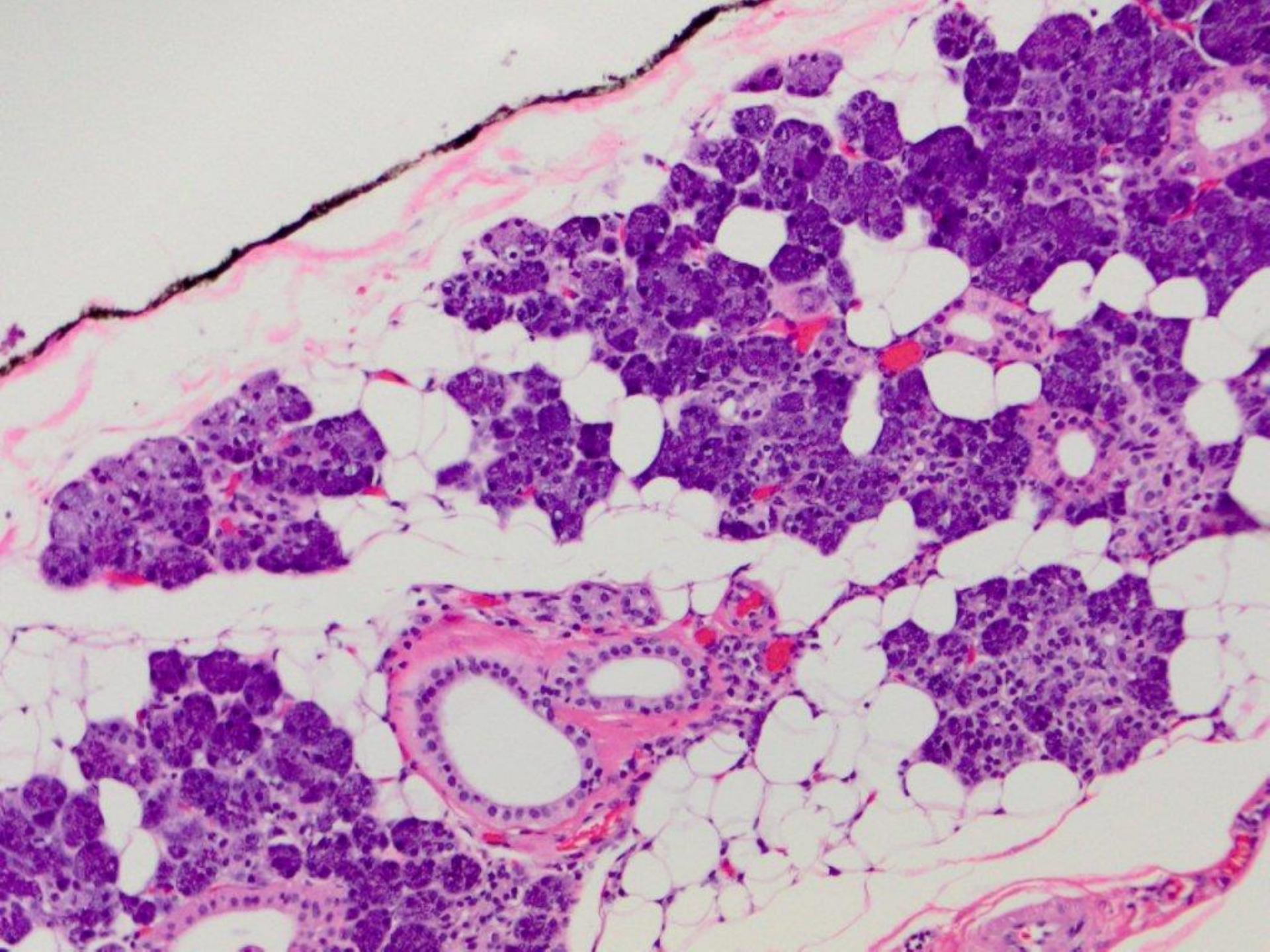


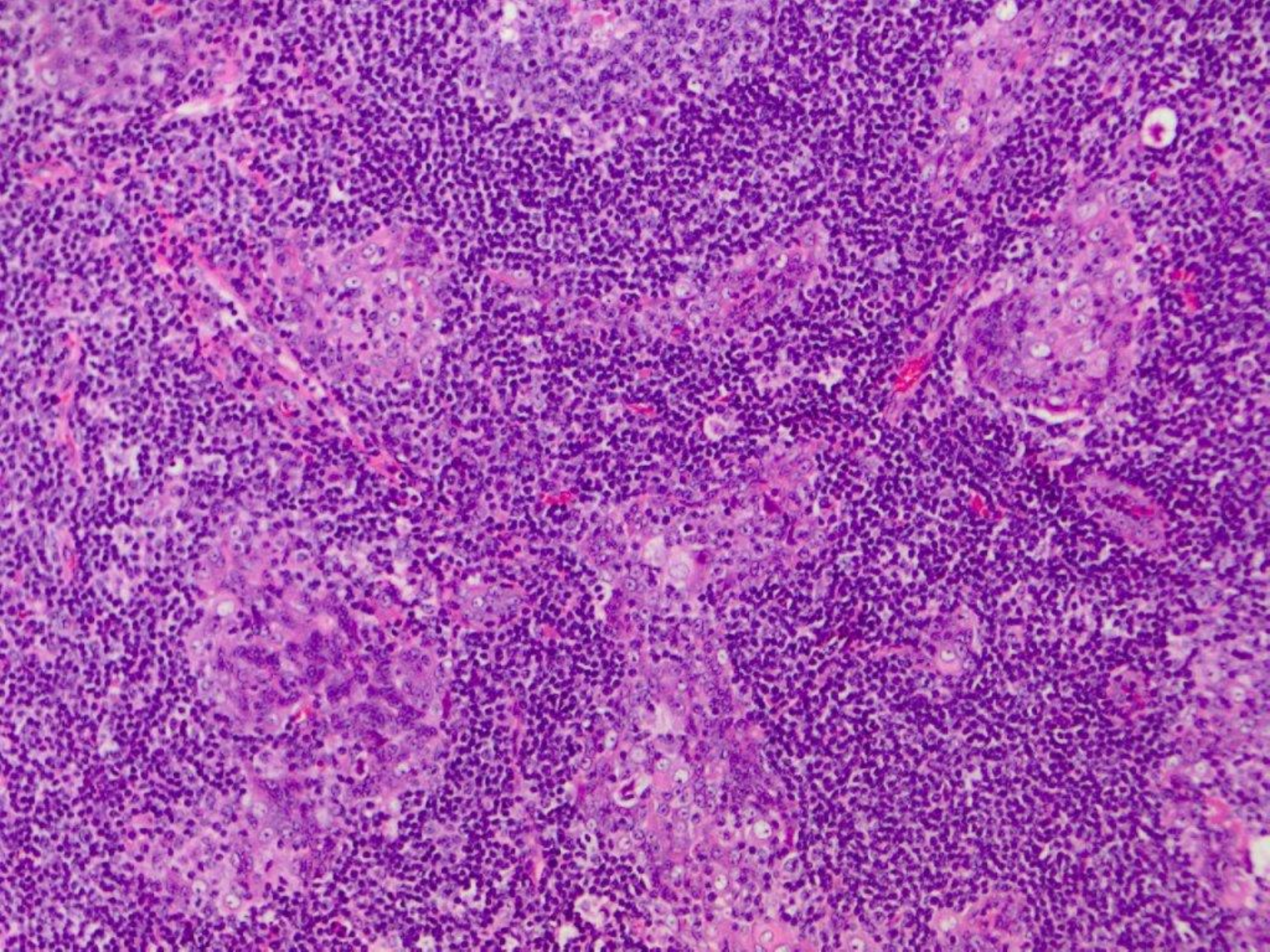


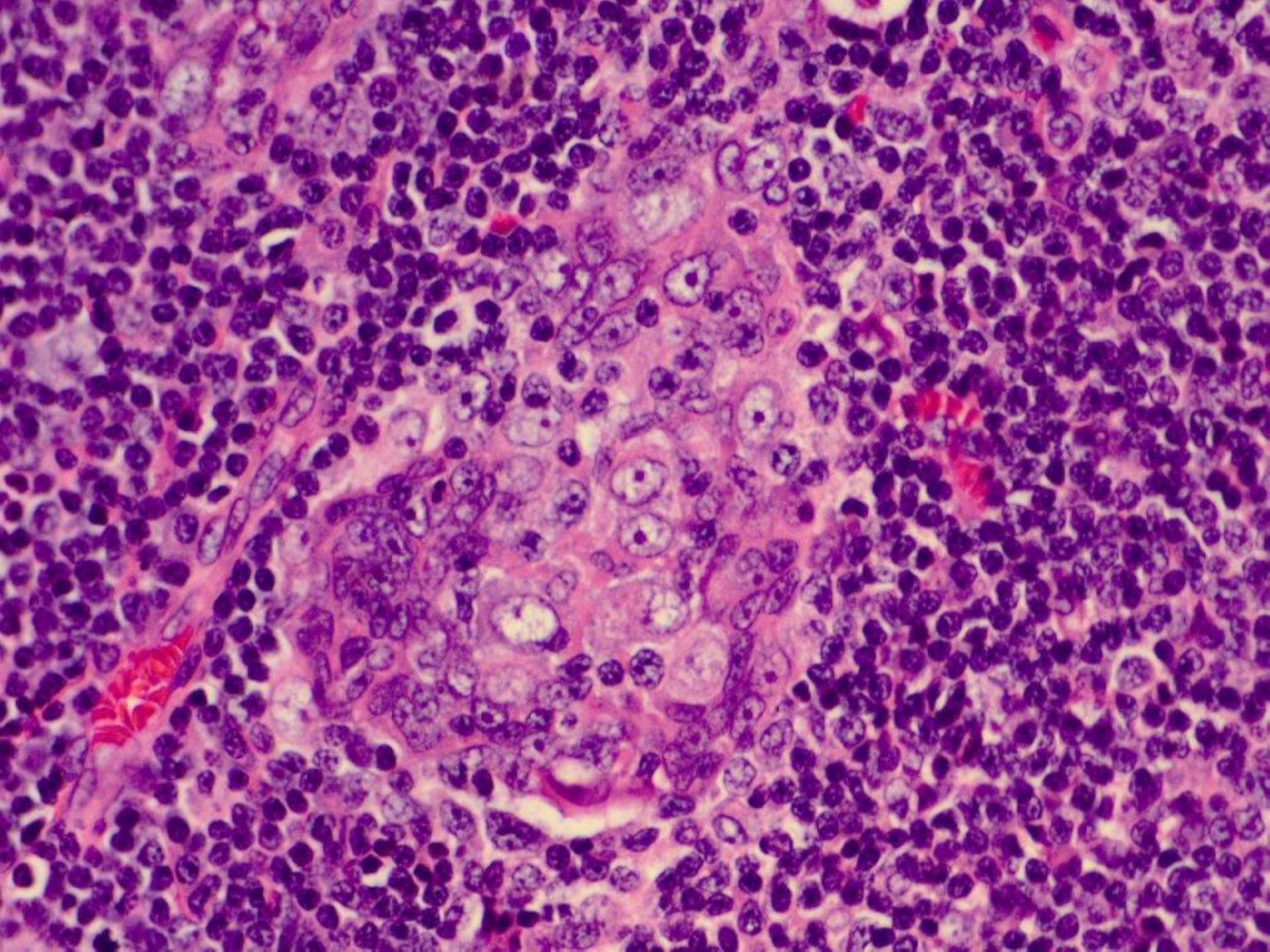
plasmacytoma

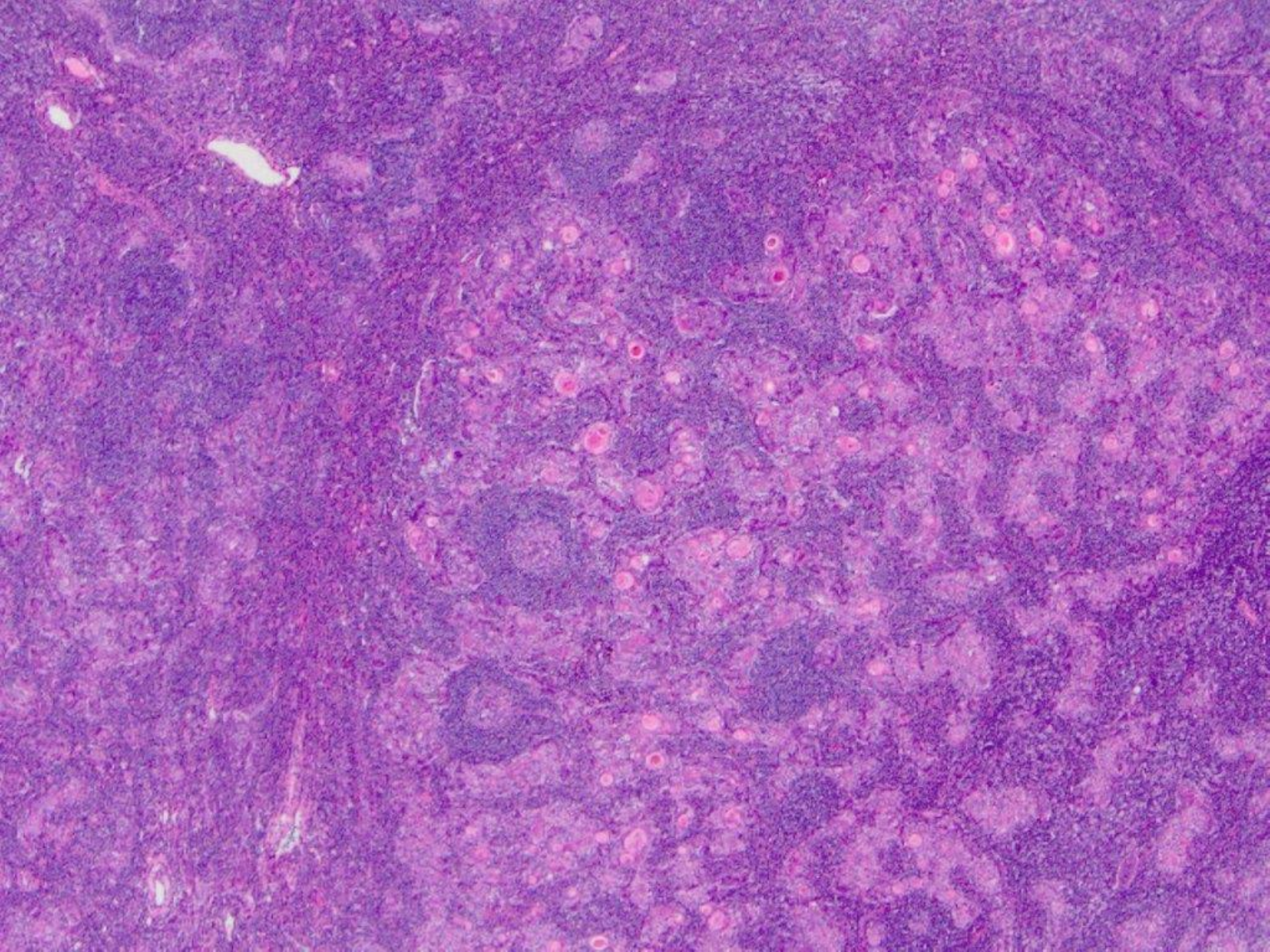


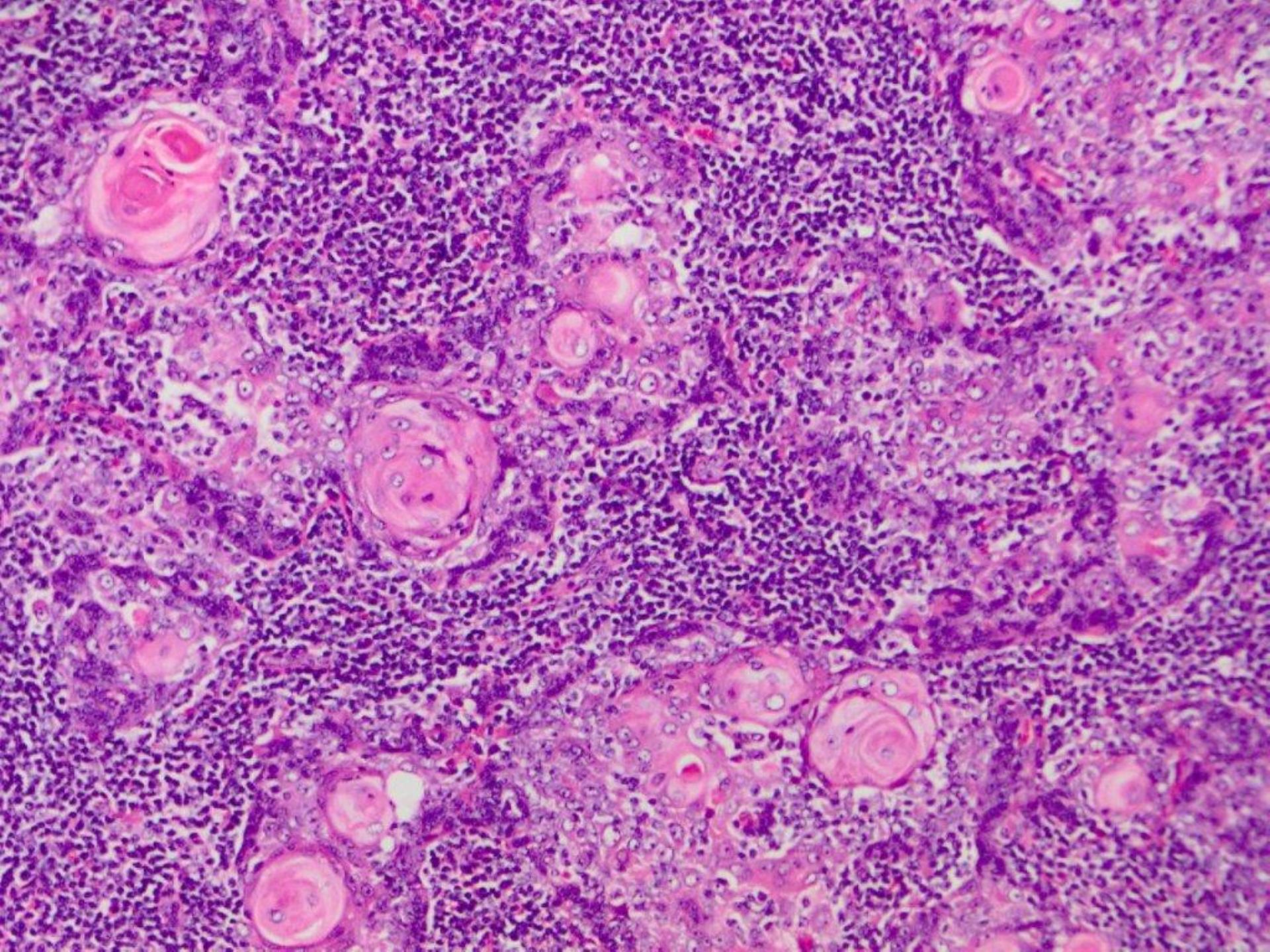


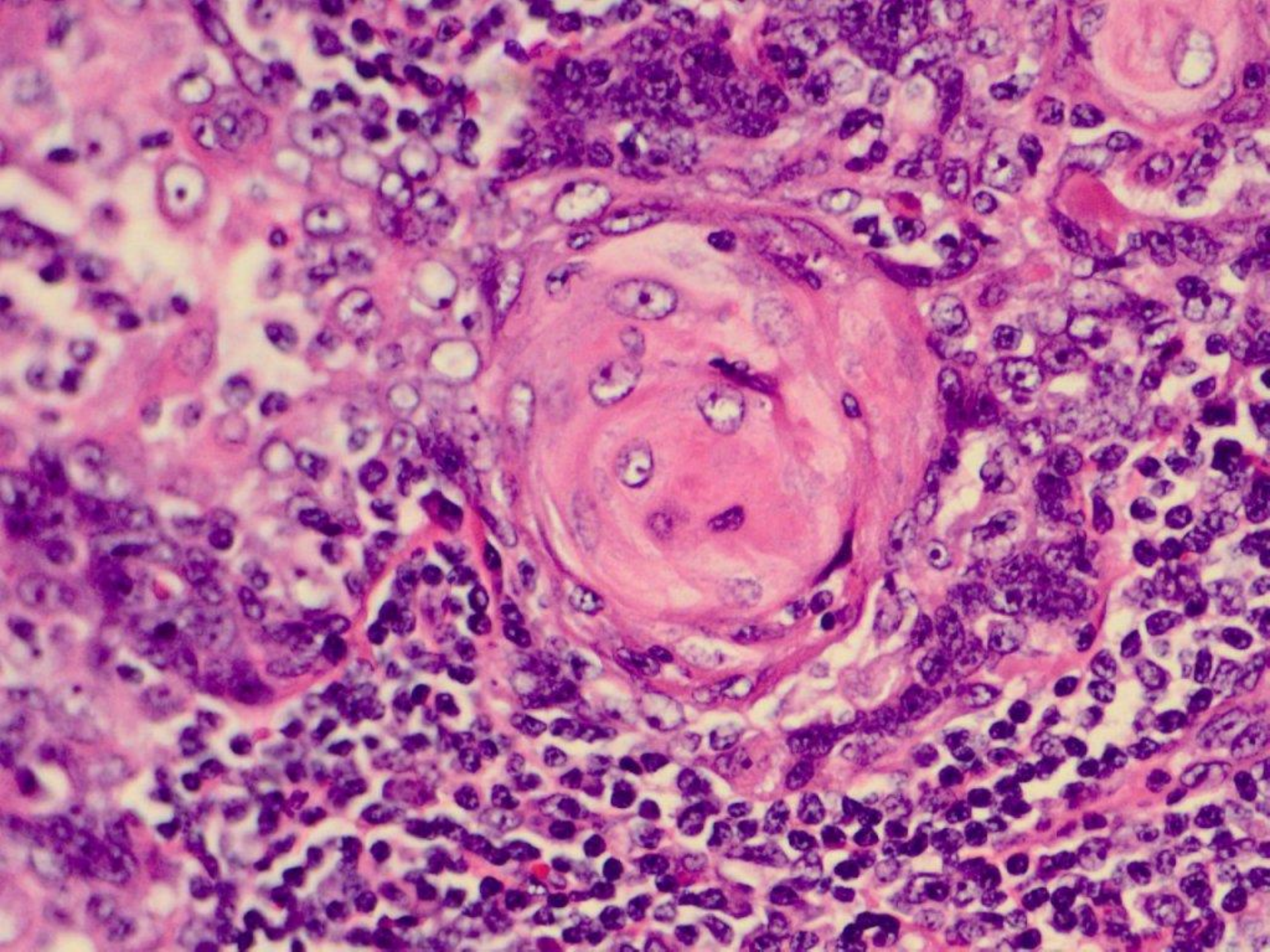


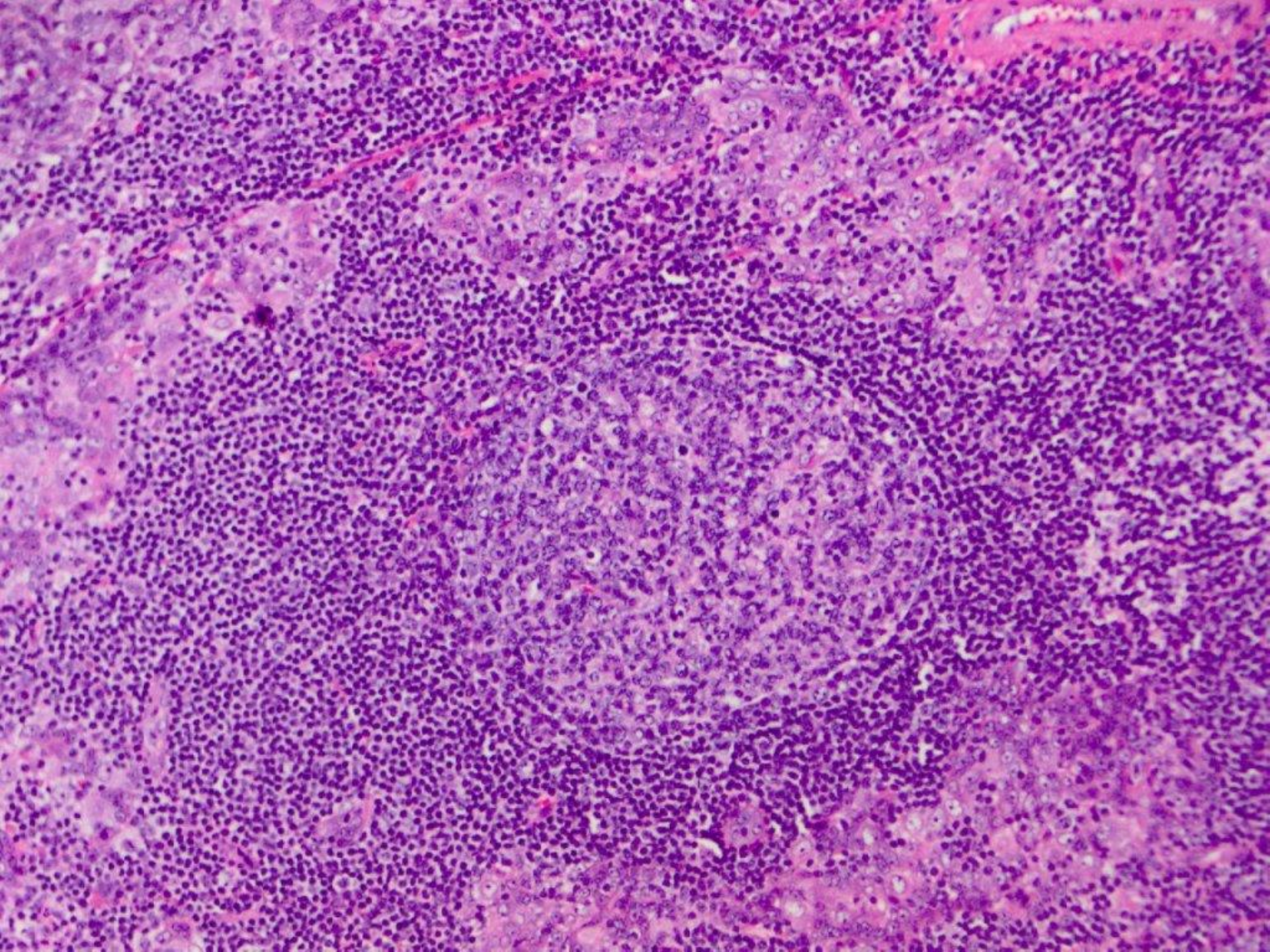


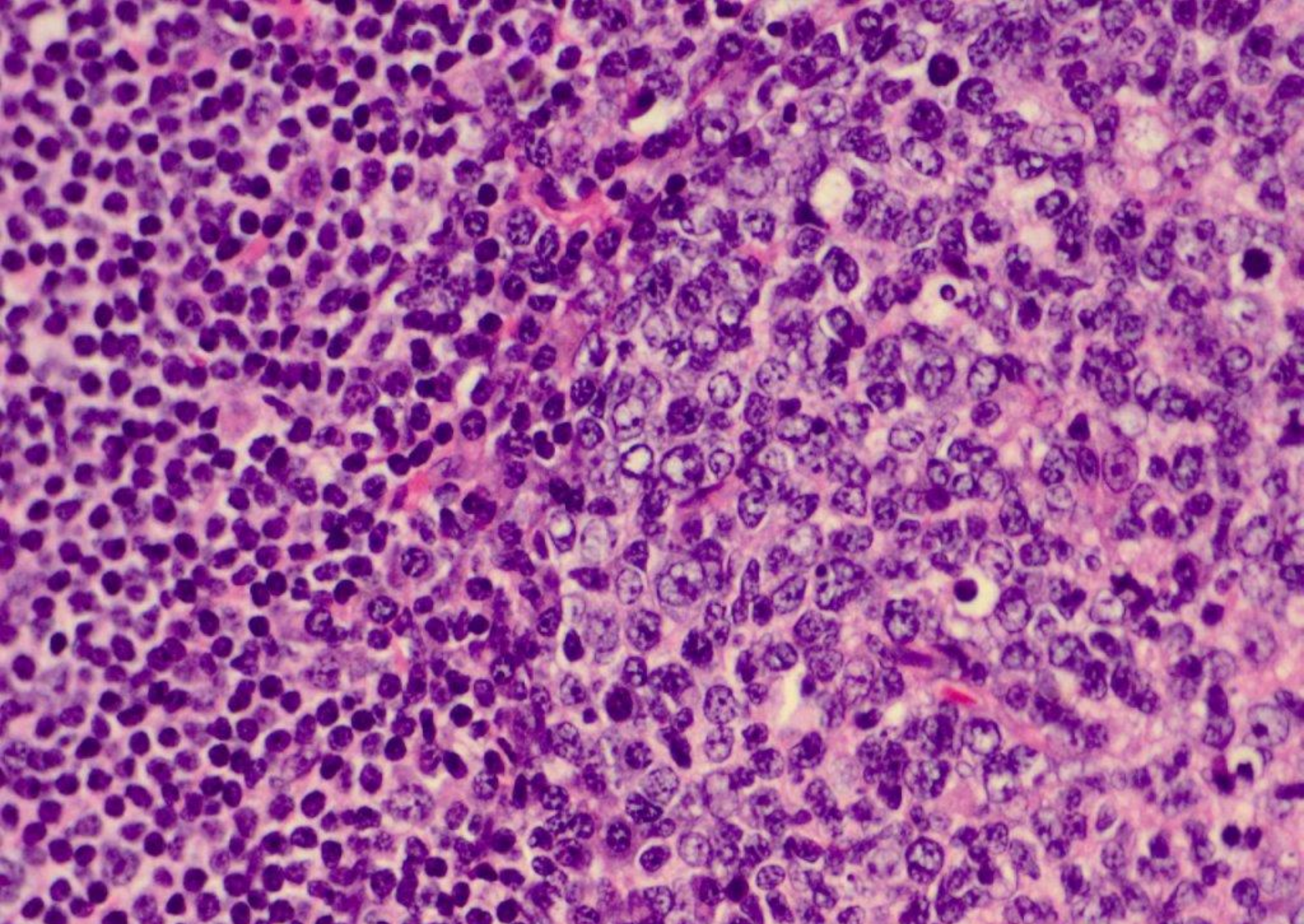




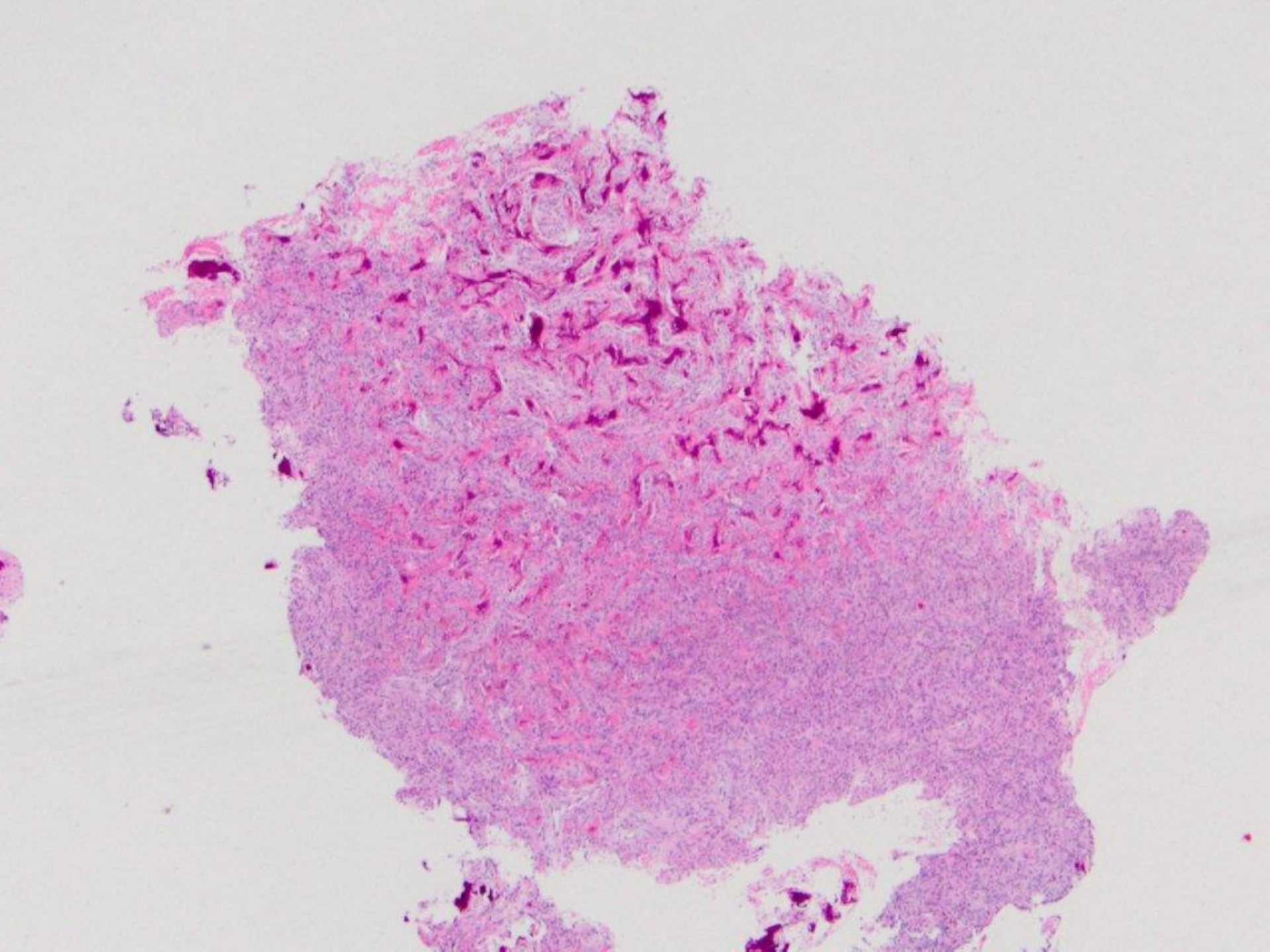


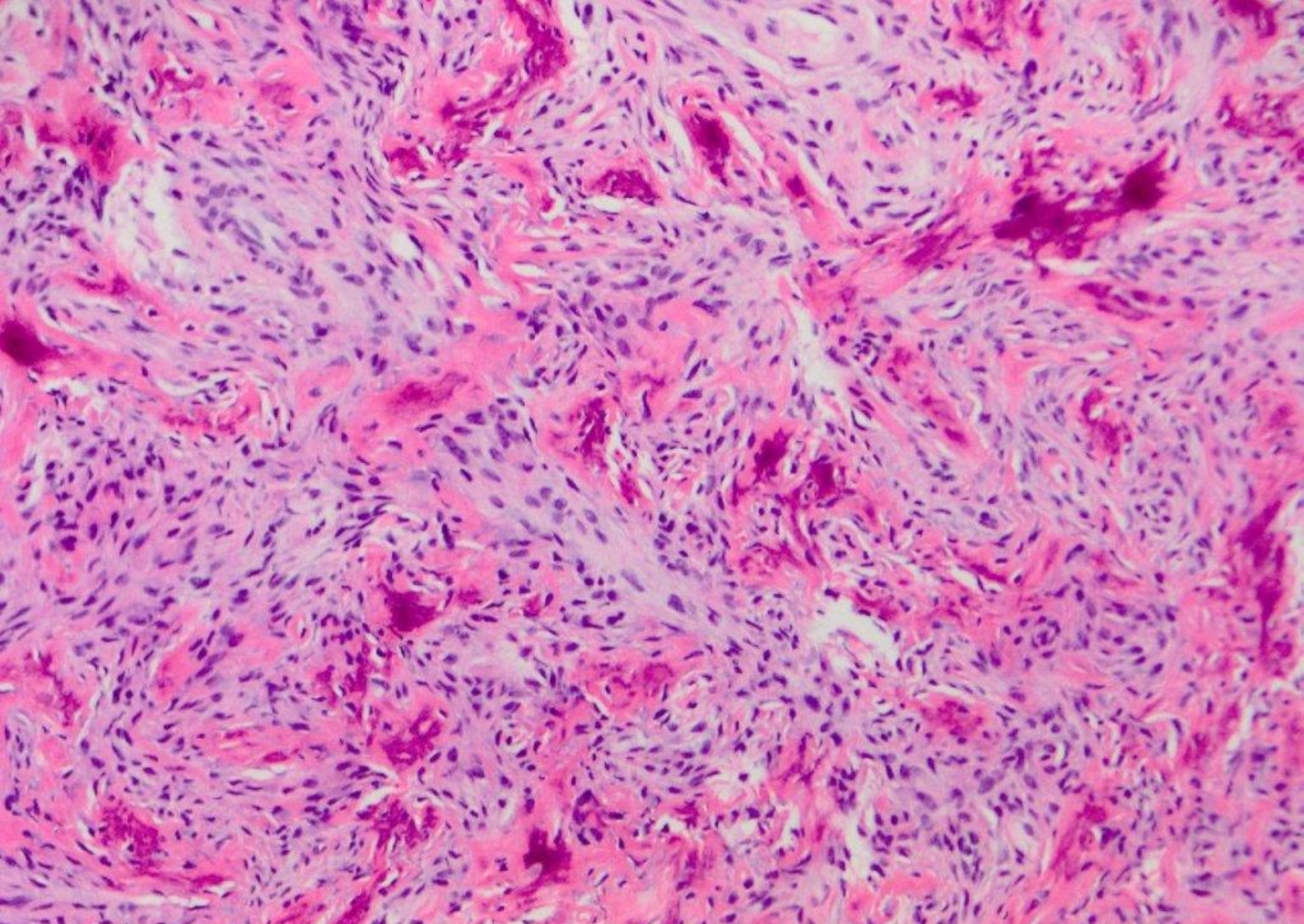




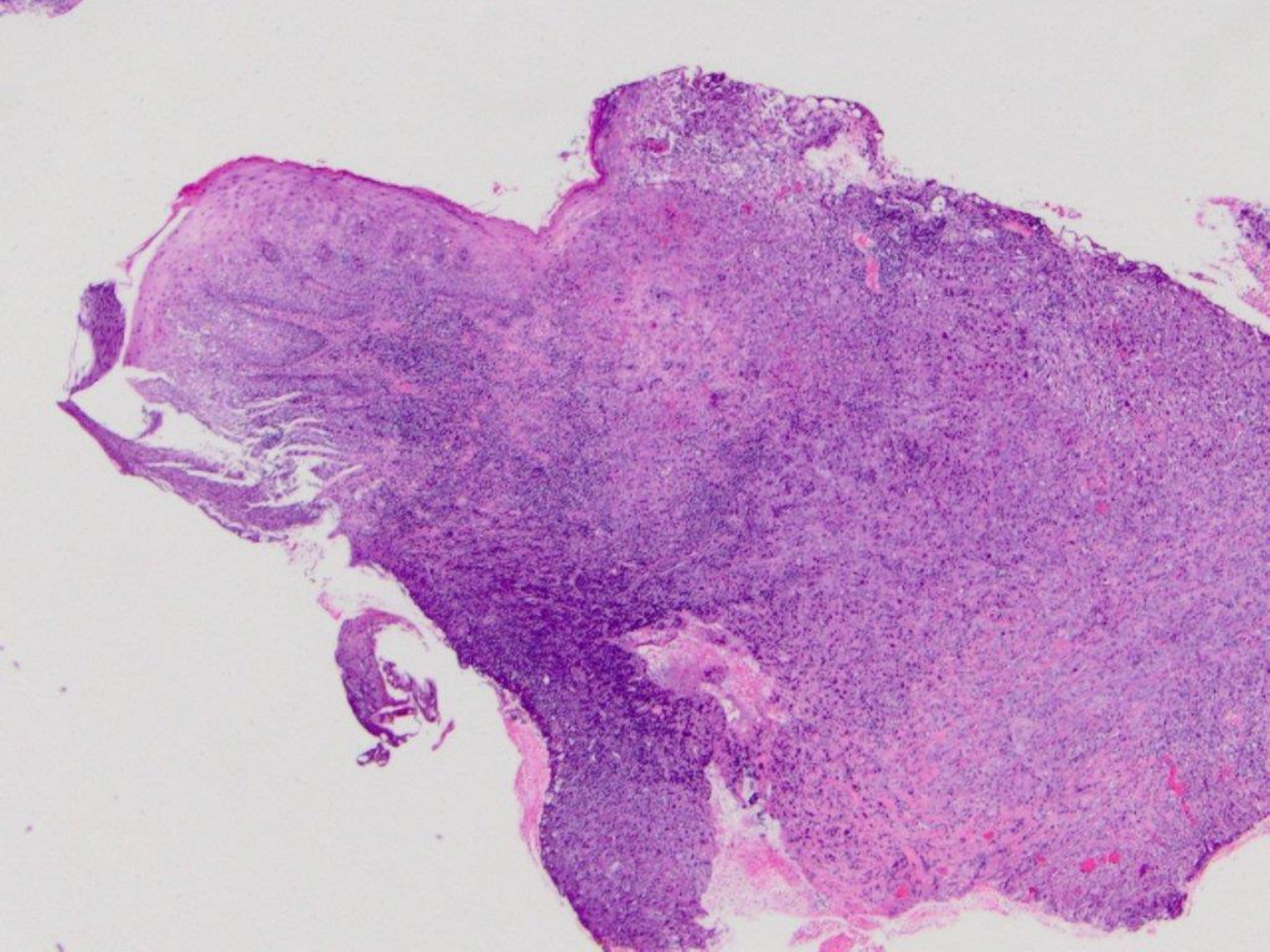


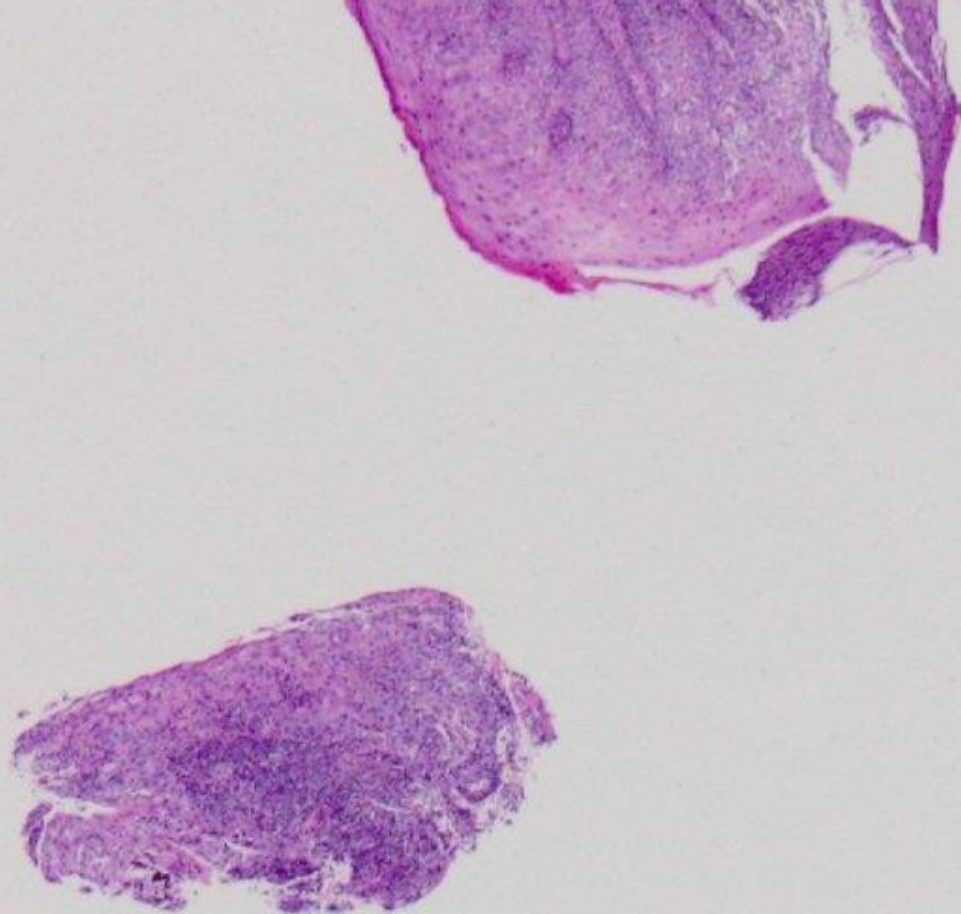
lymphoepithelial carcinoma

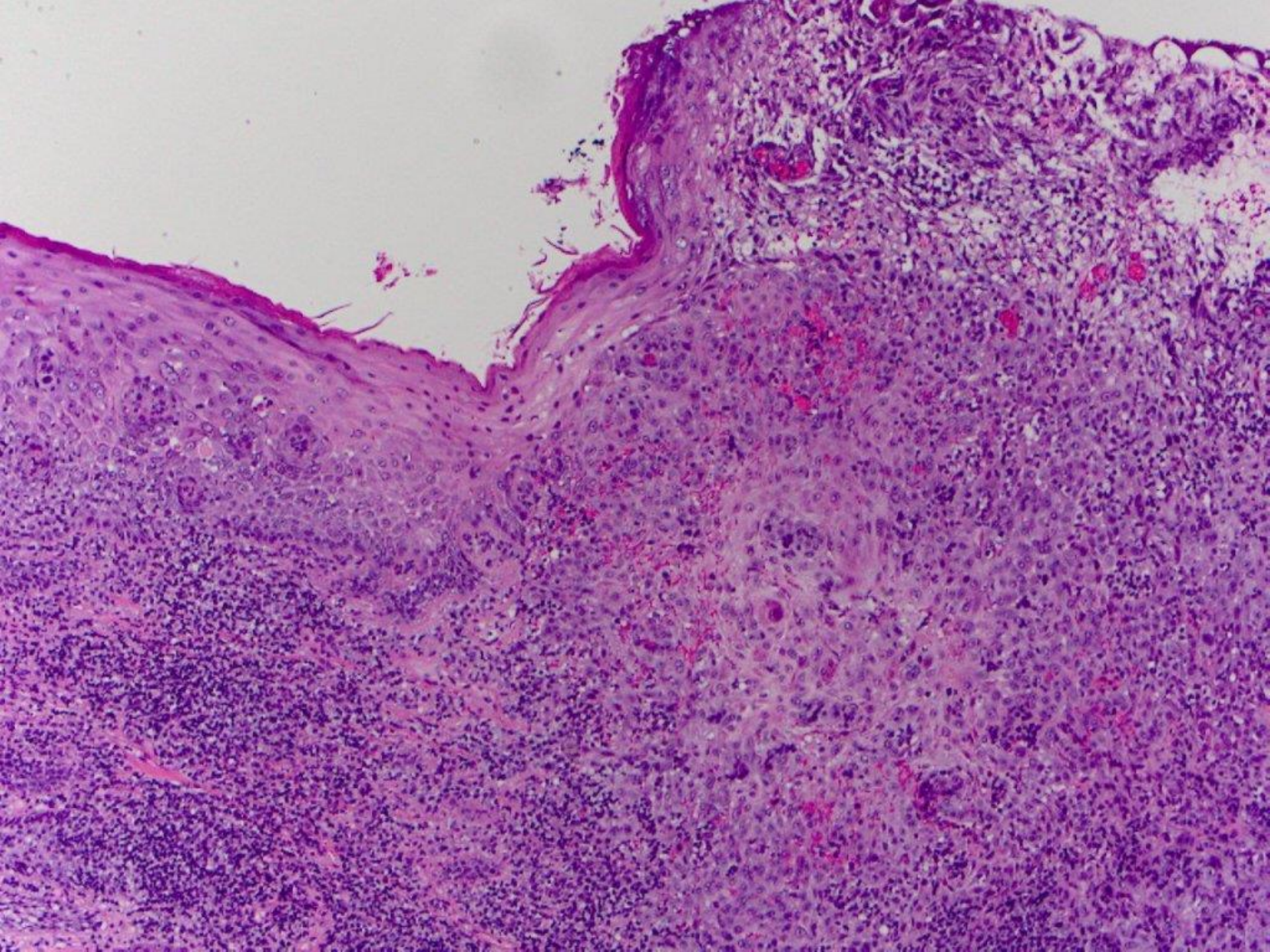


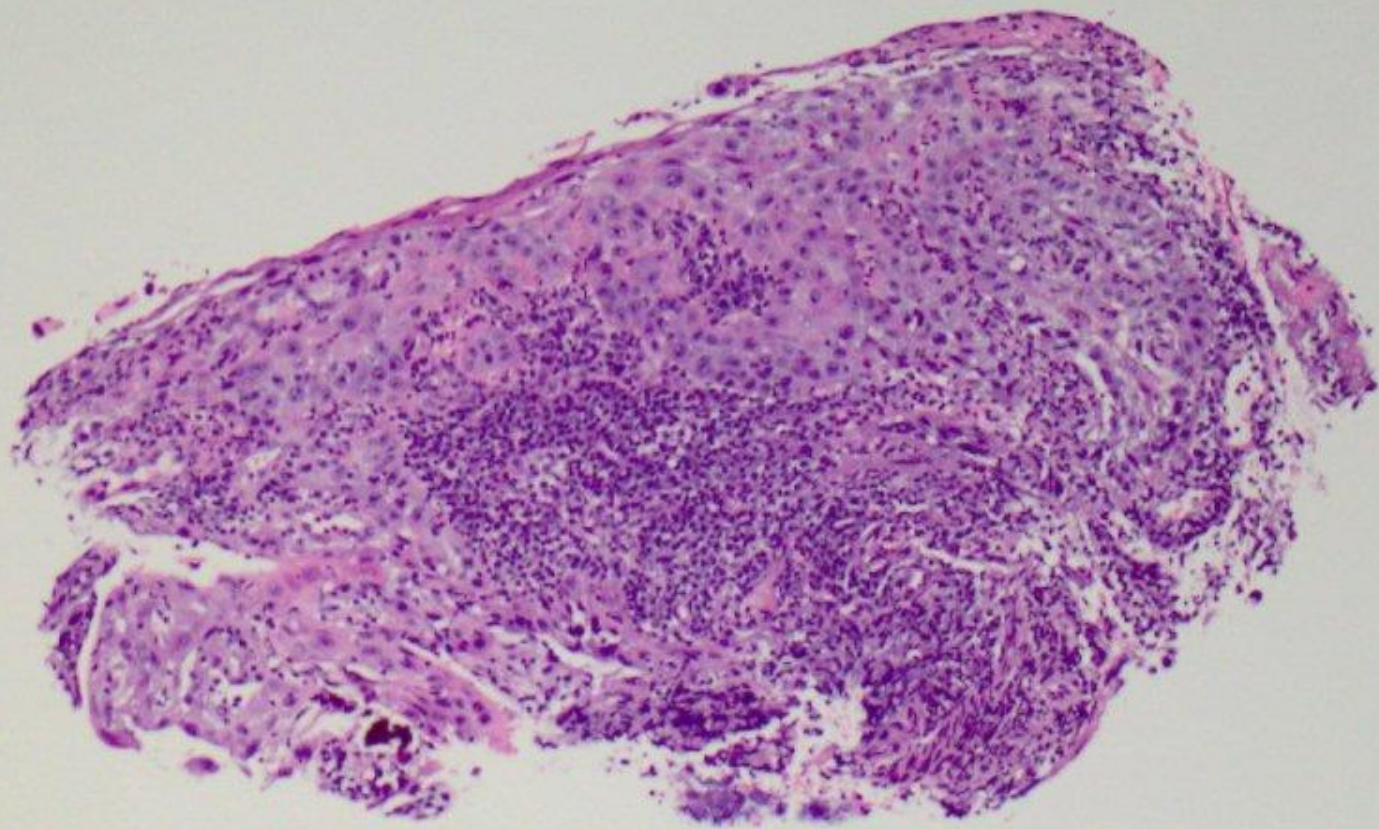


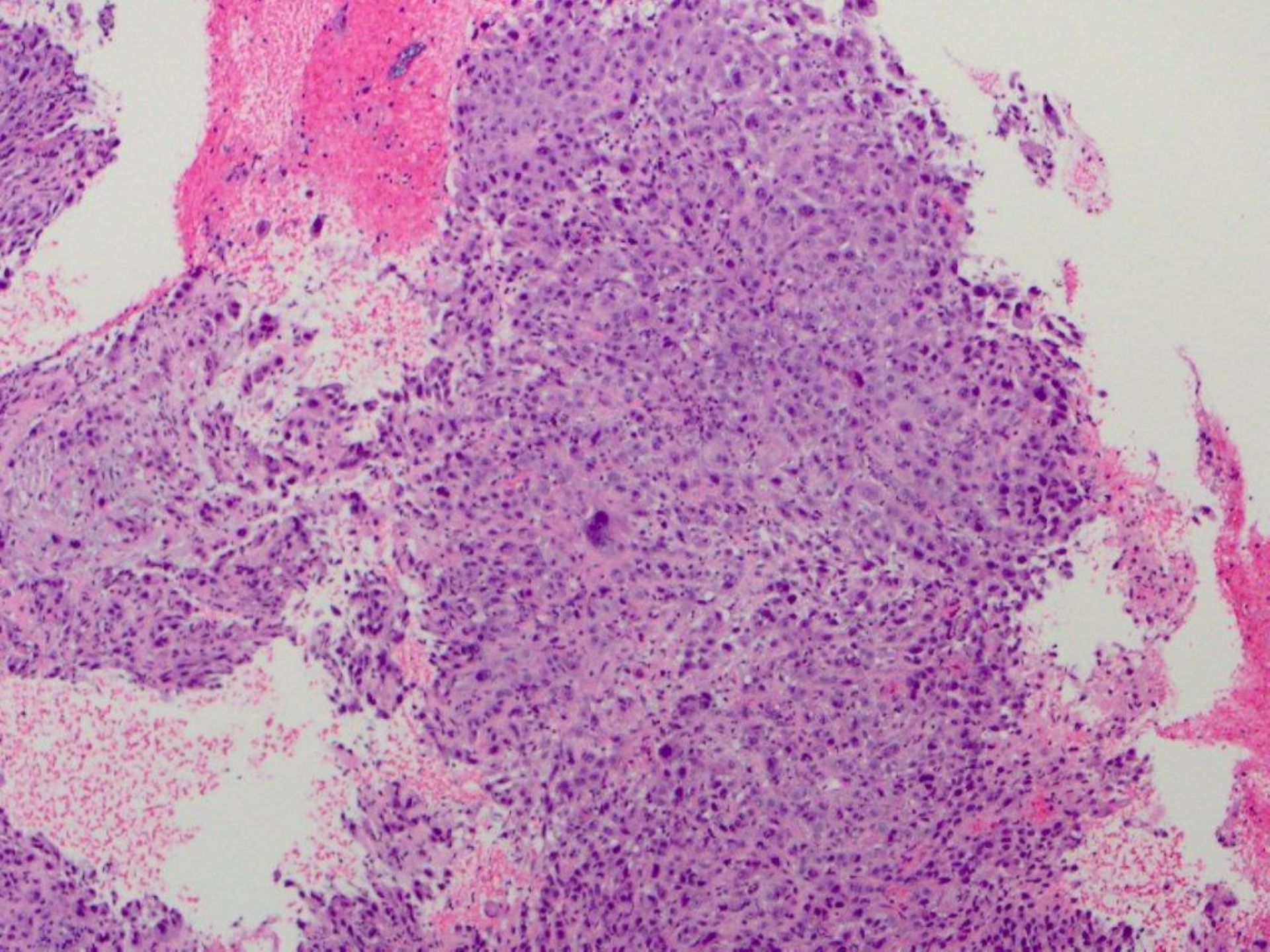
benign fibroosseous lesion

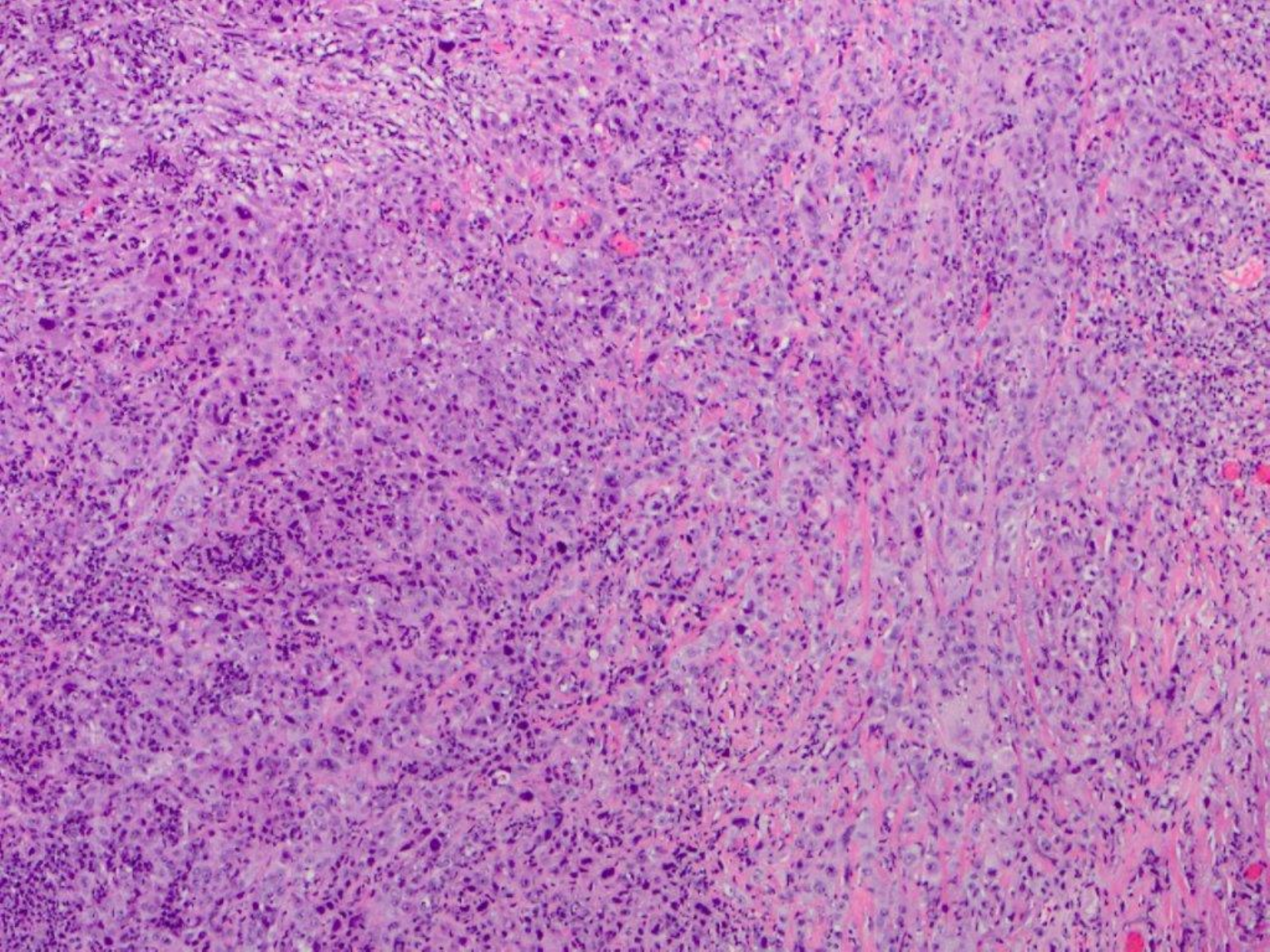


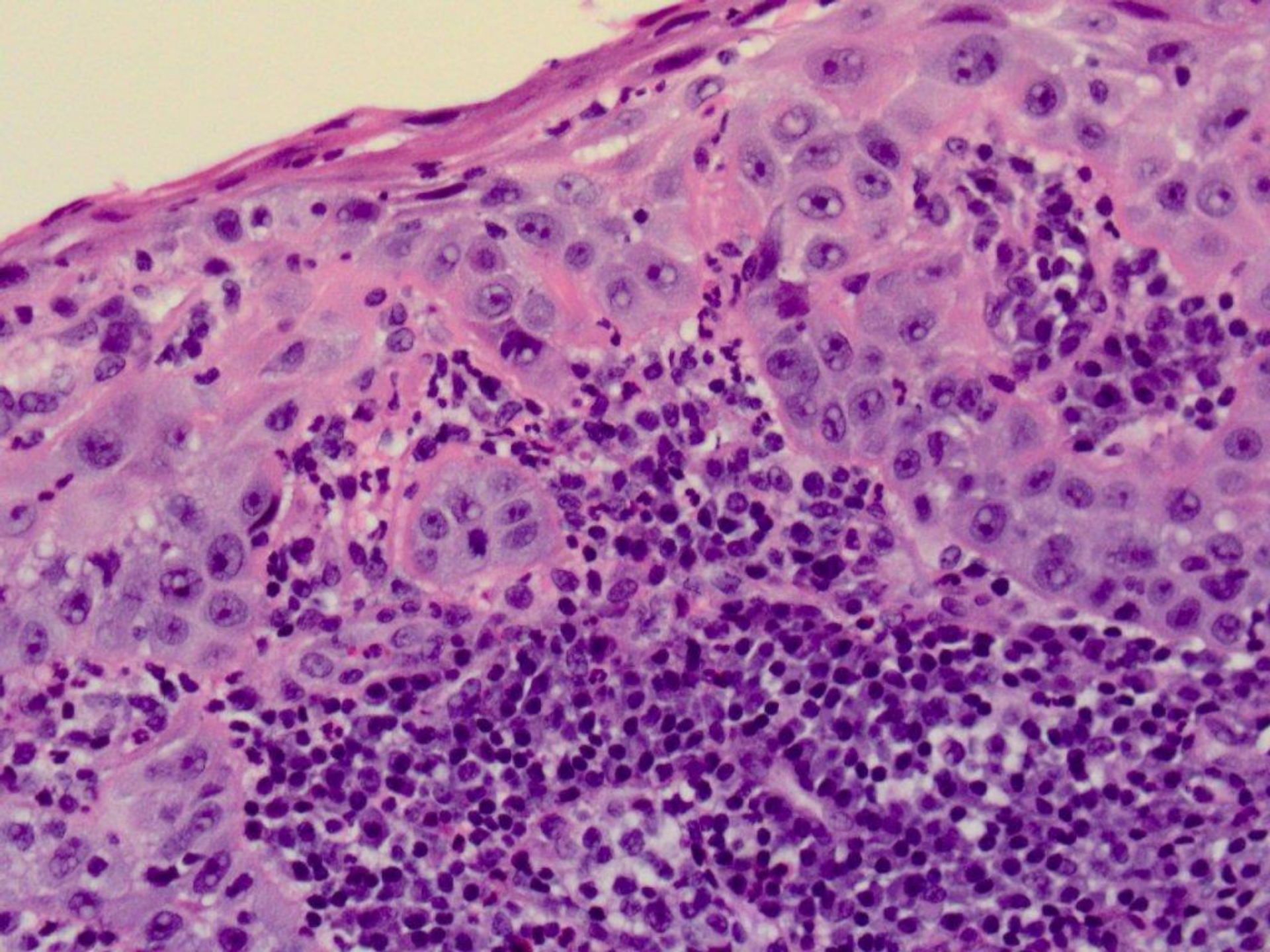


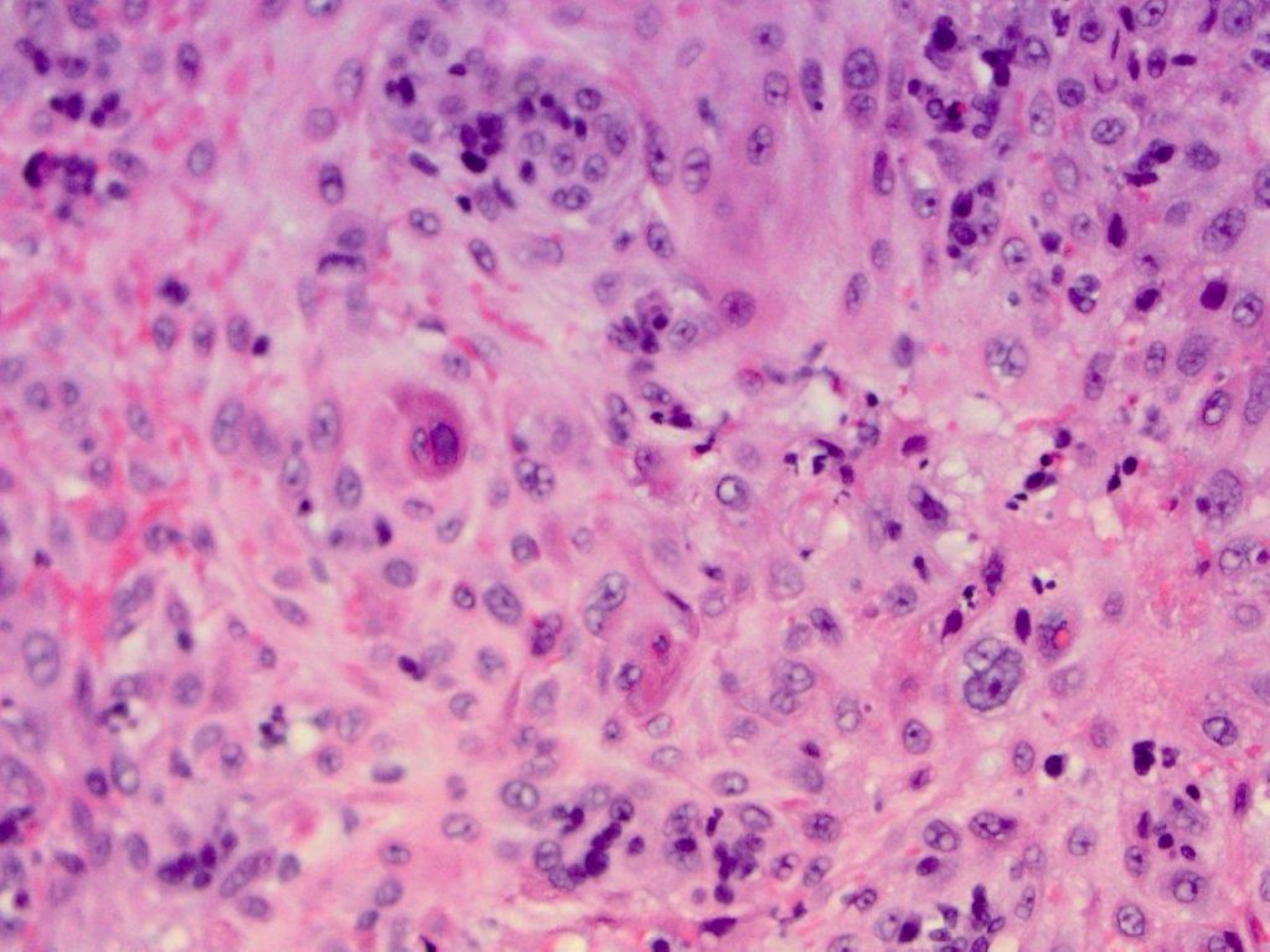


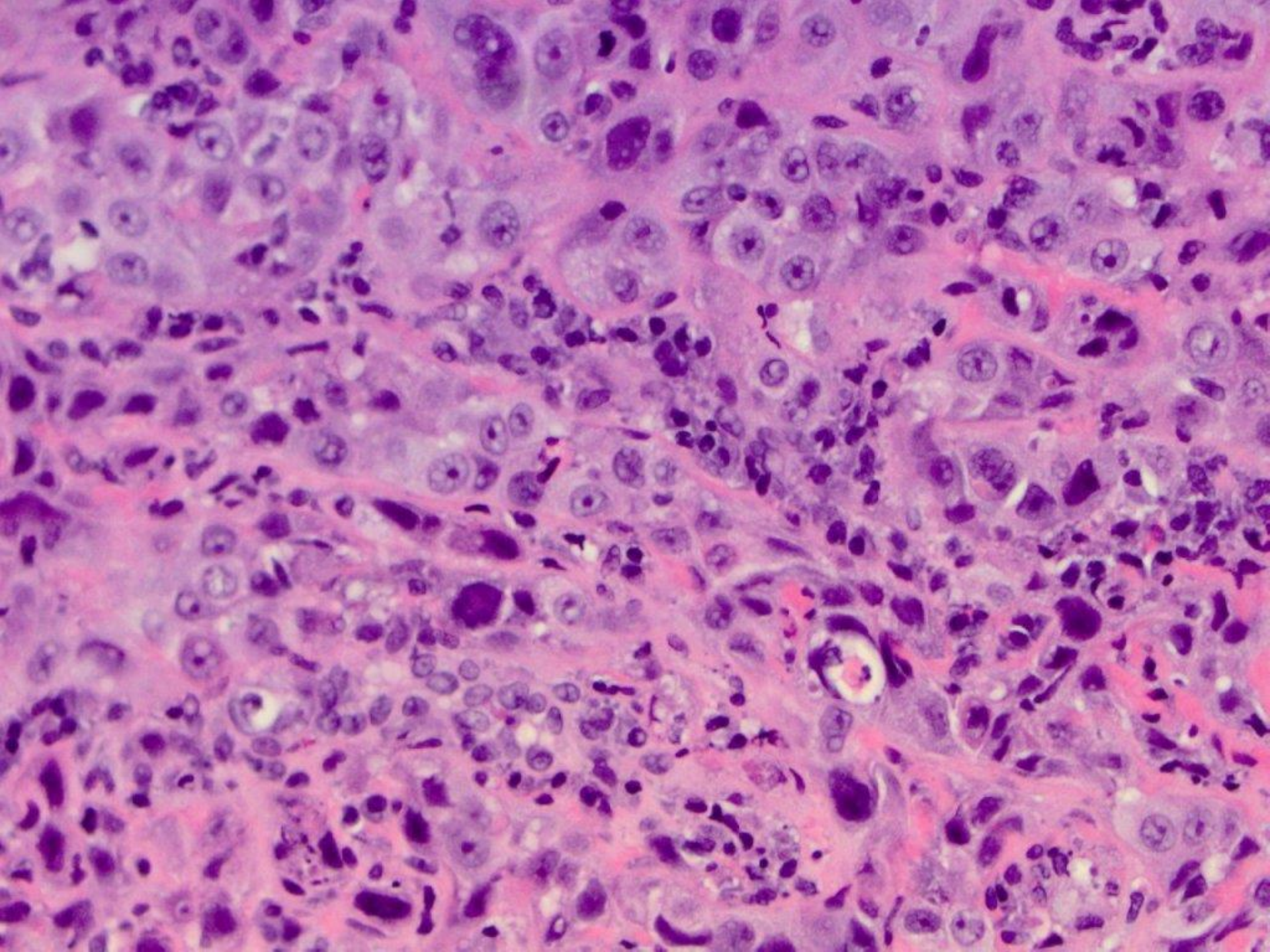


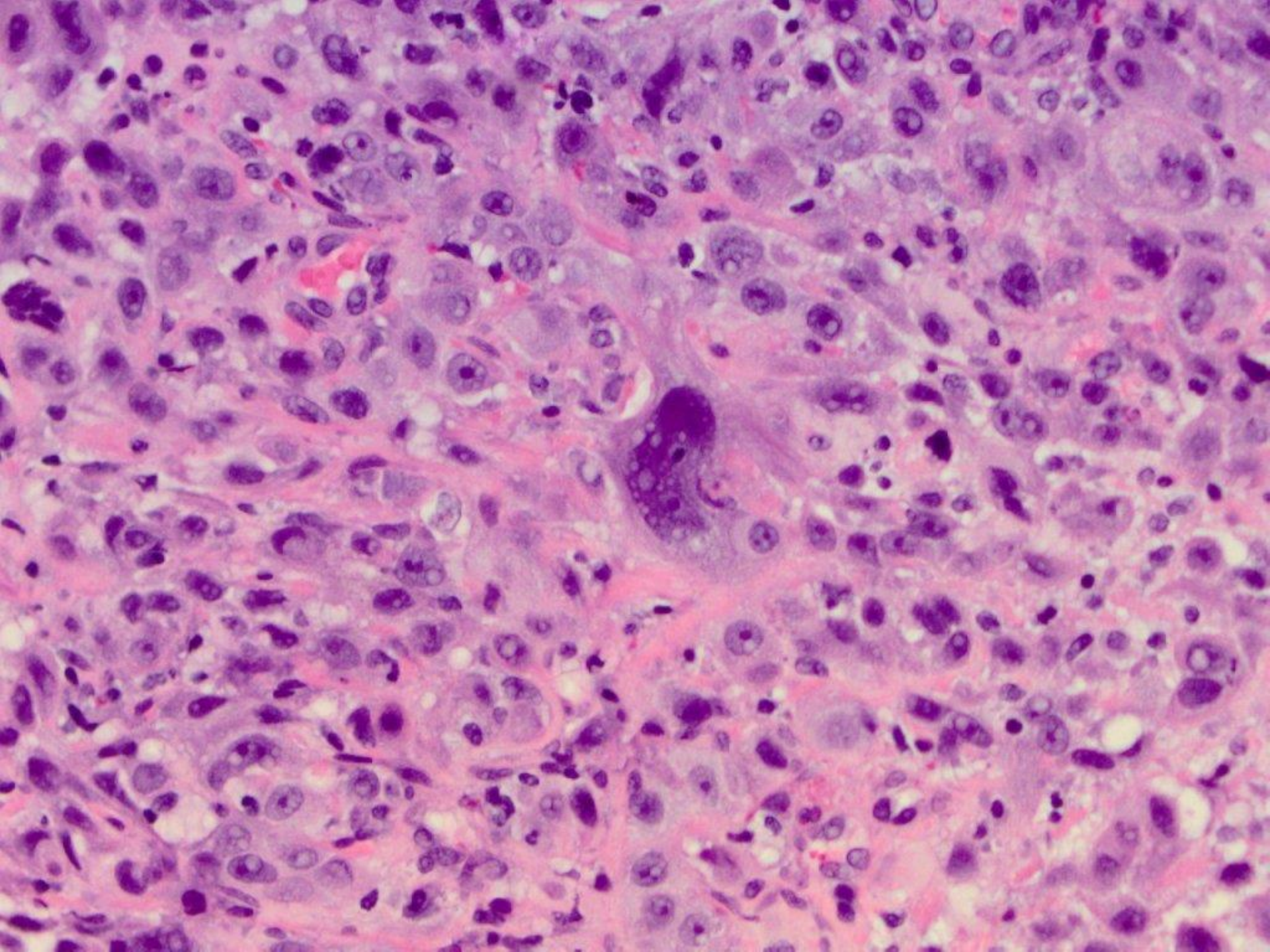


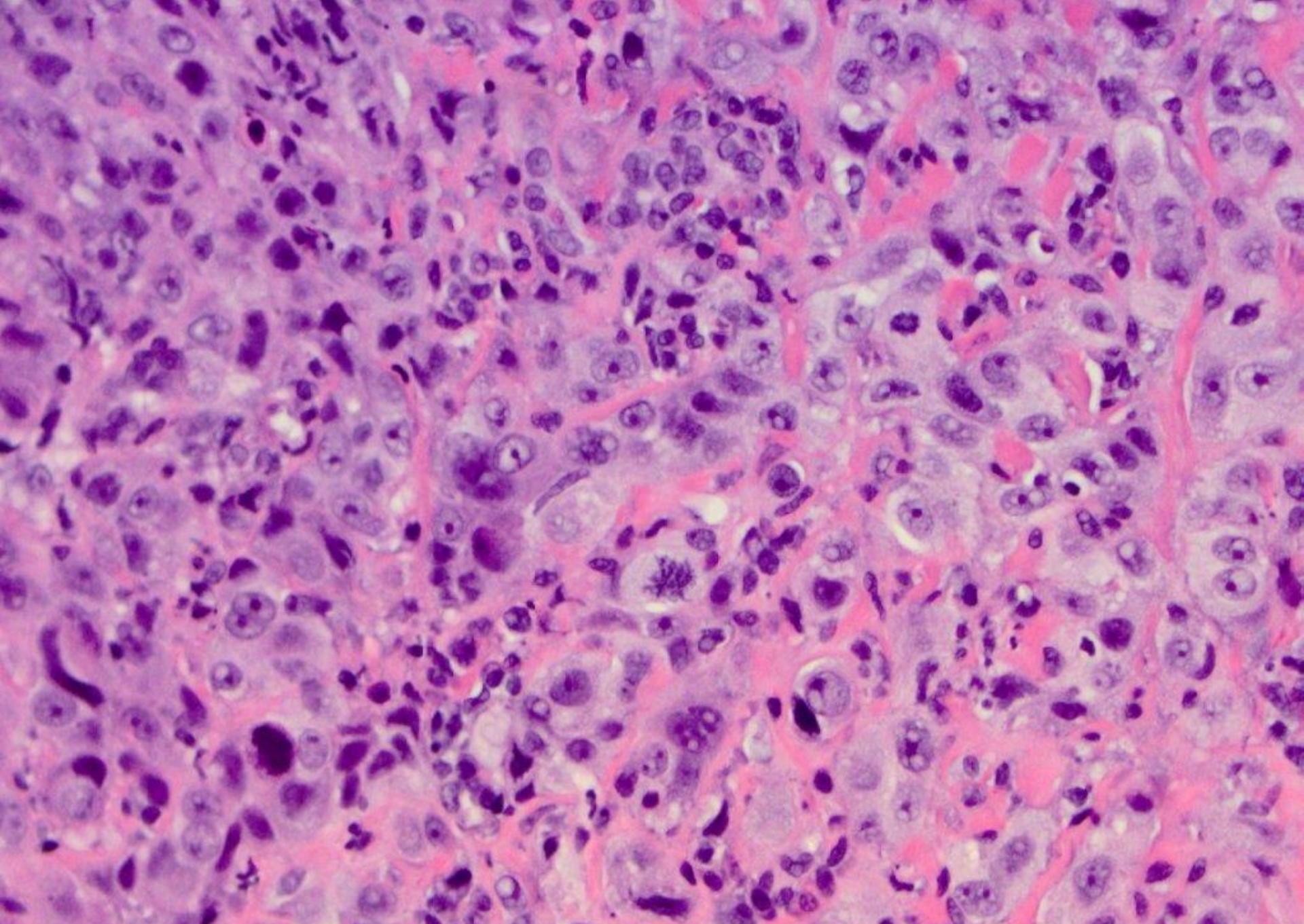




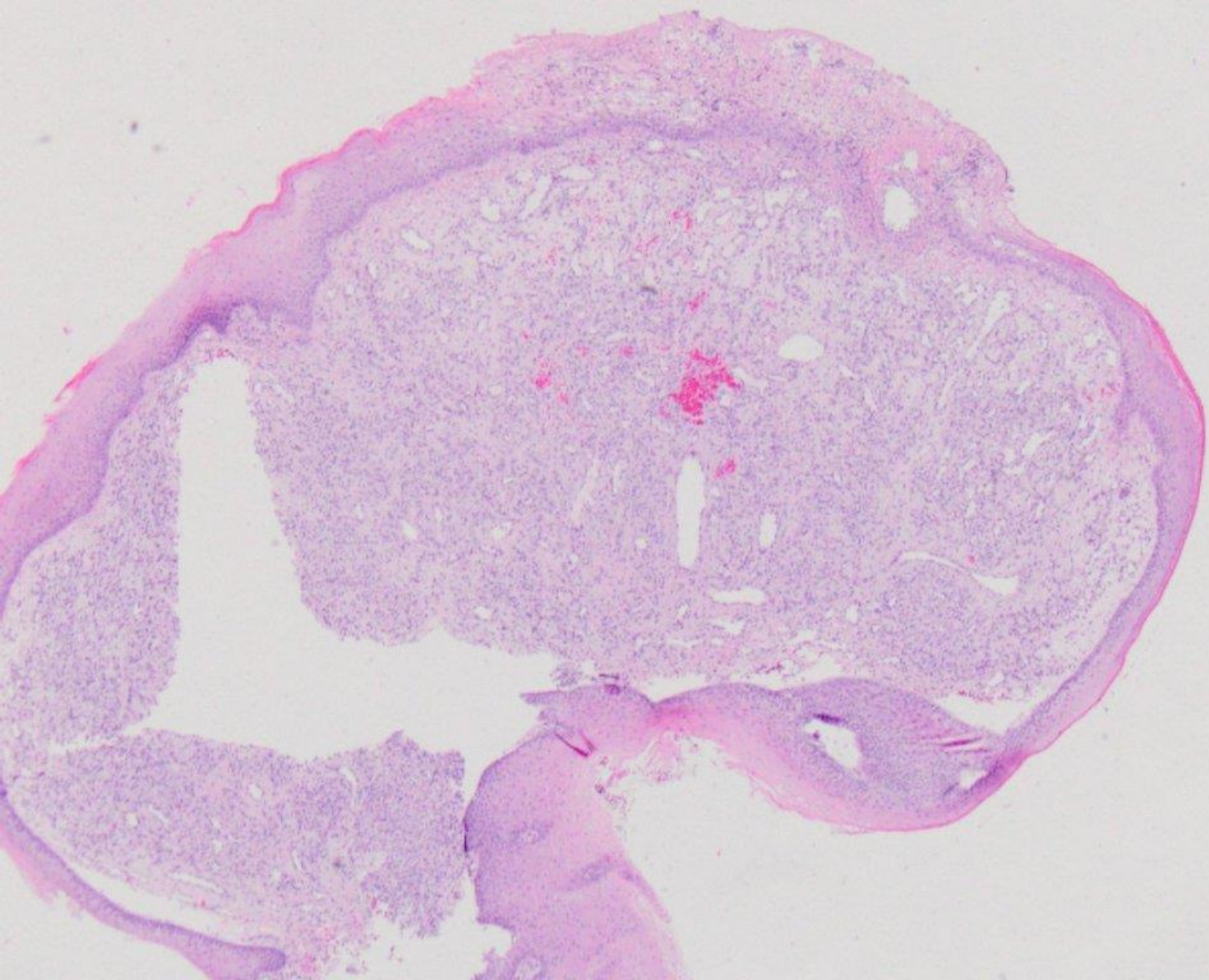


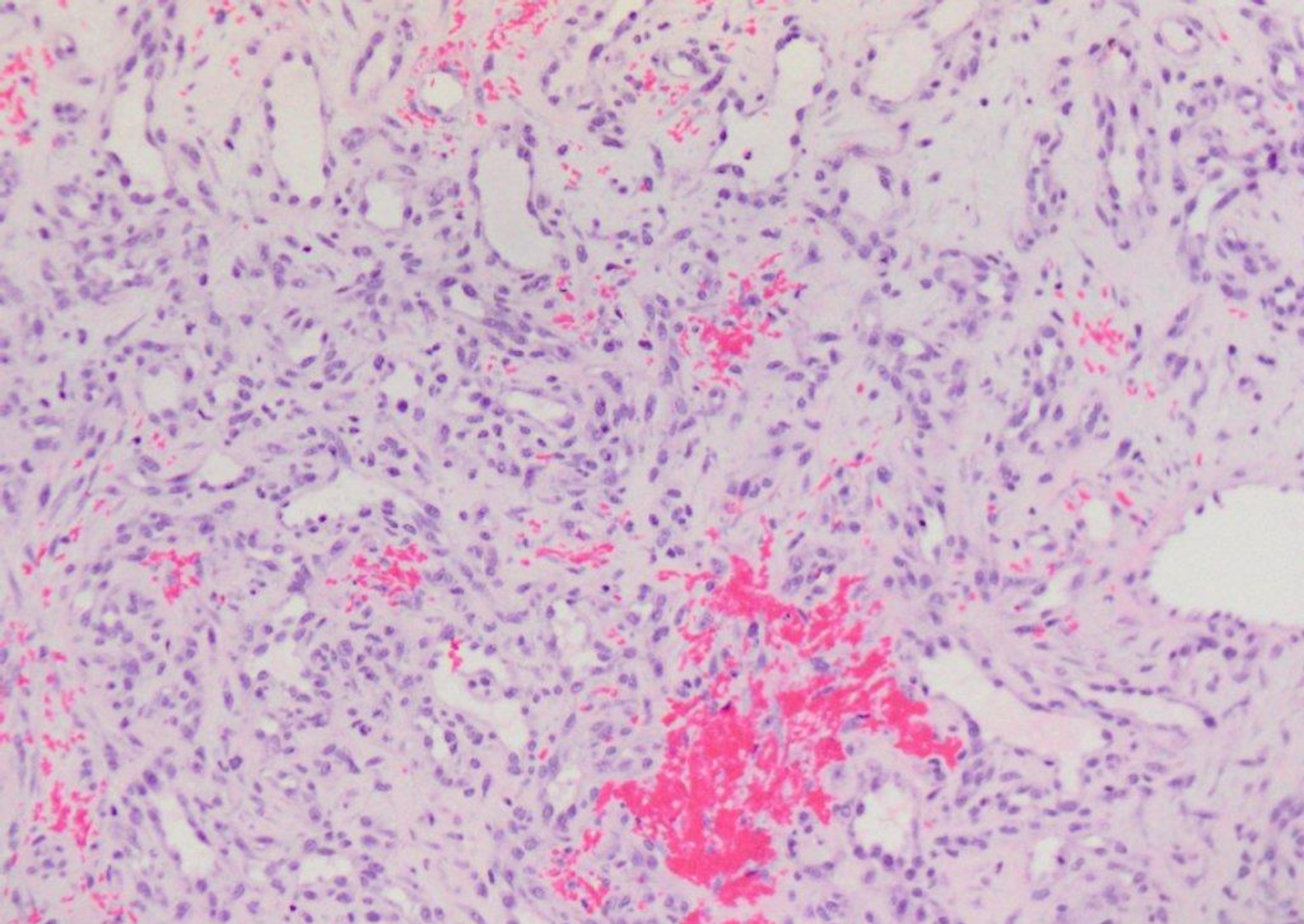




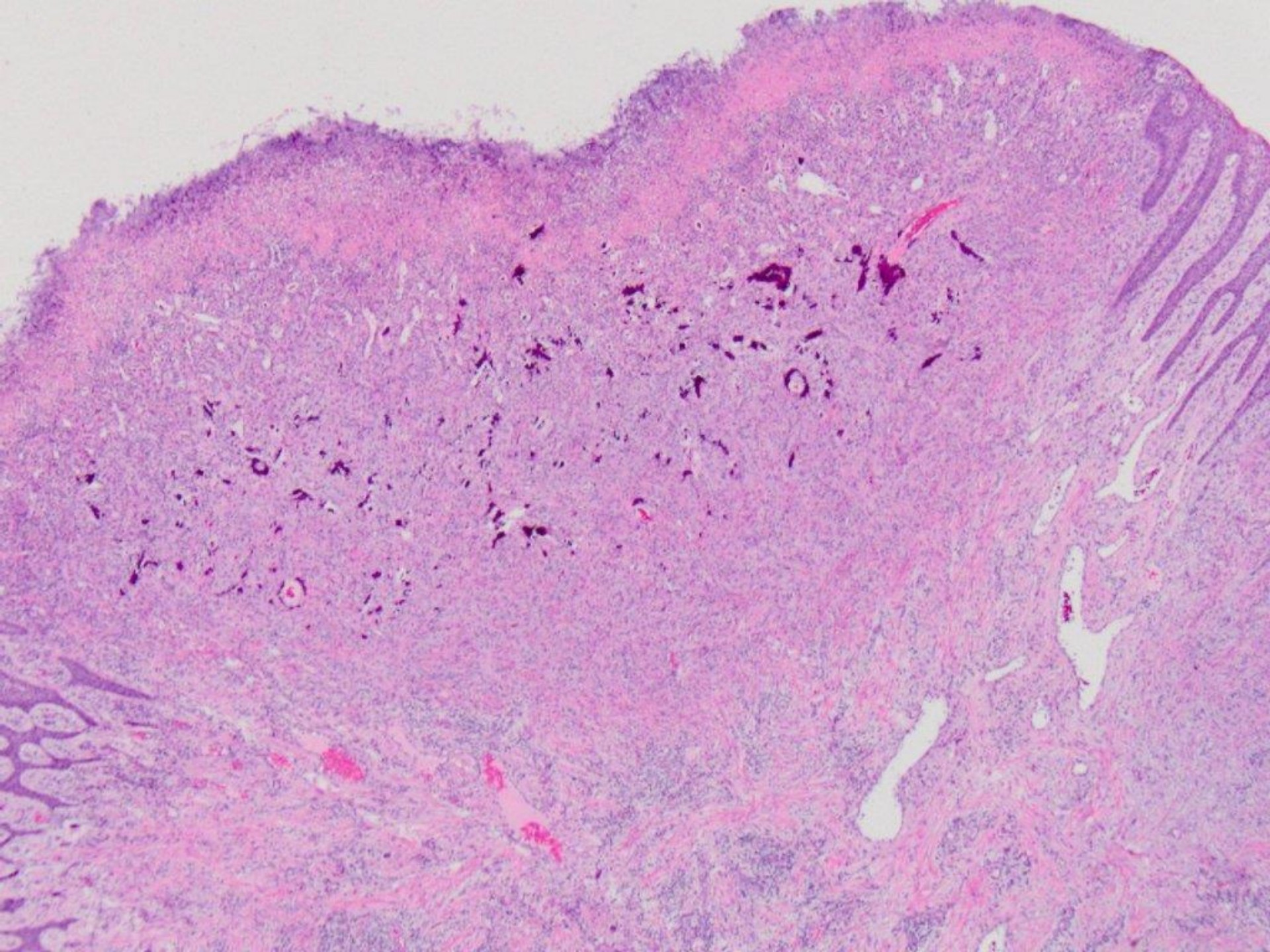


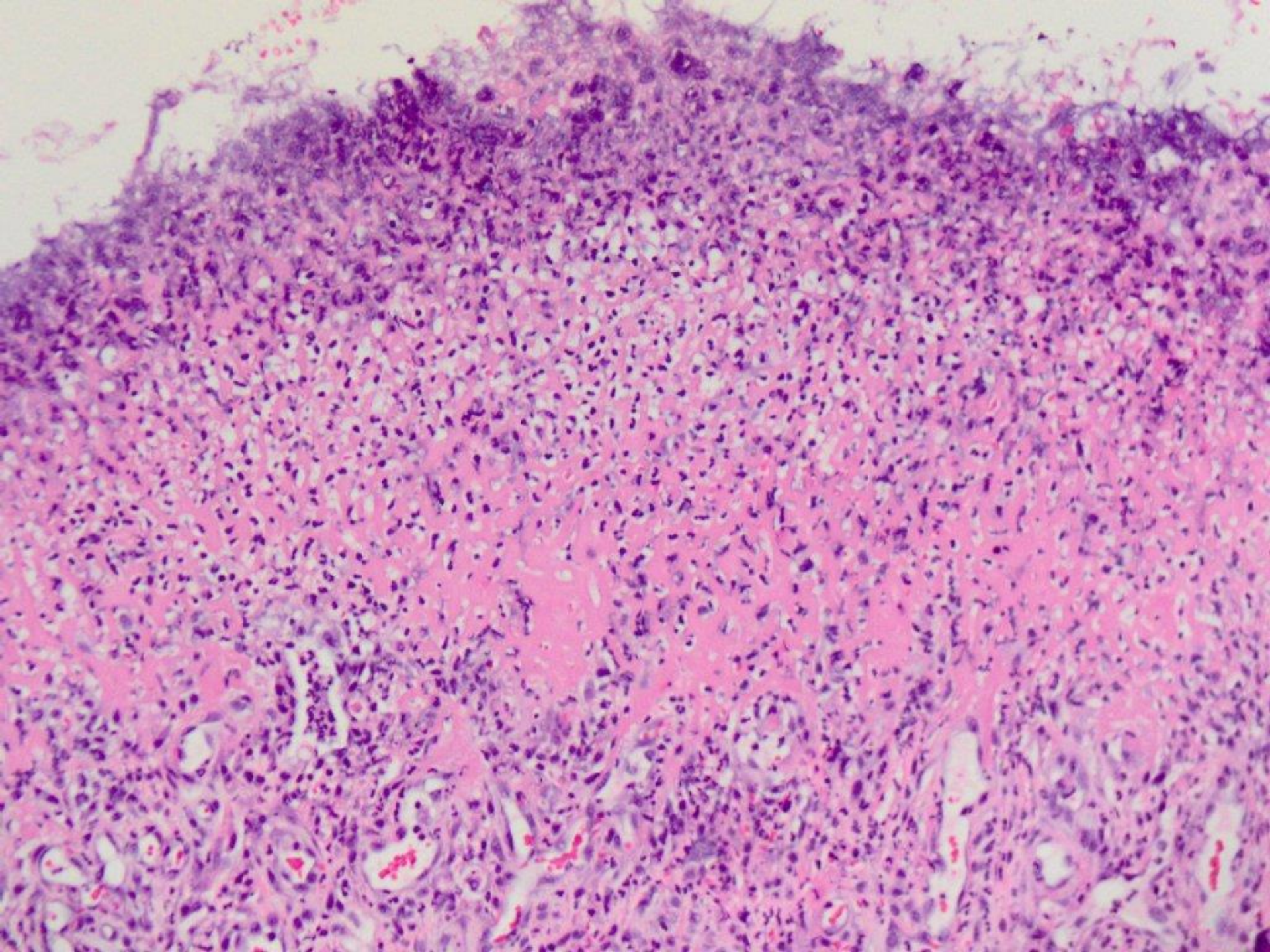
squamous cell carcinoma

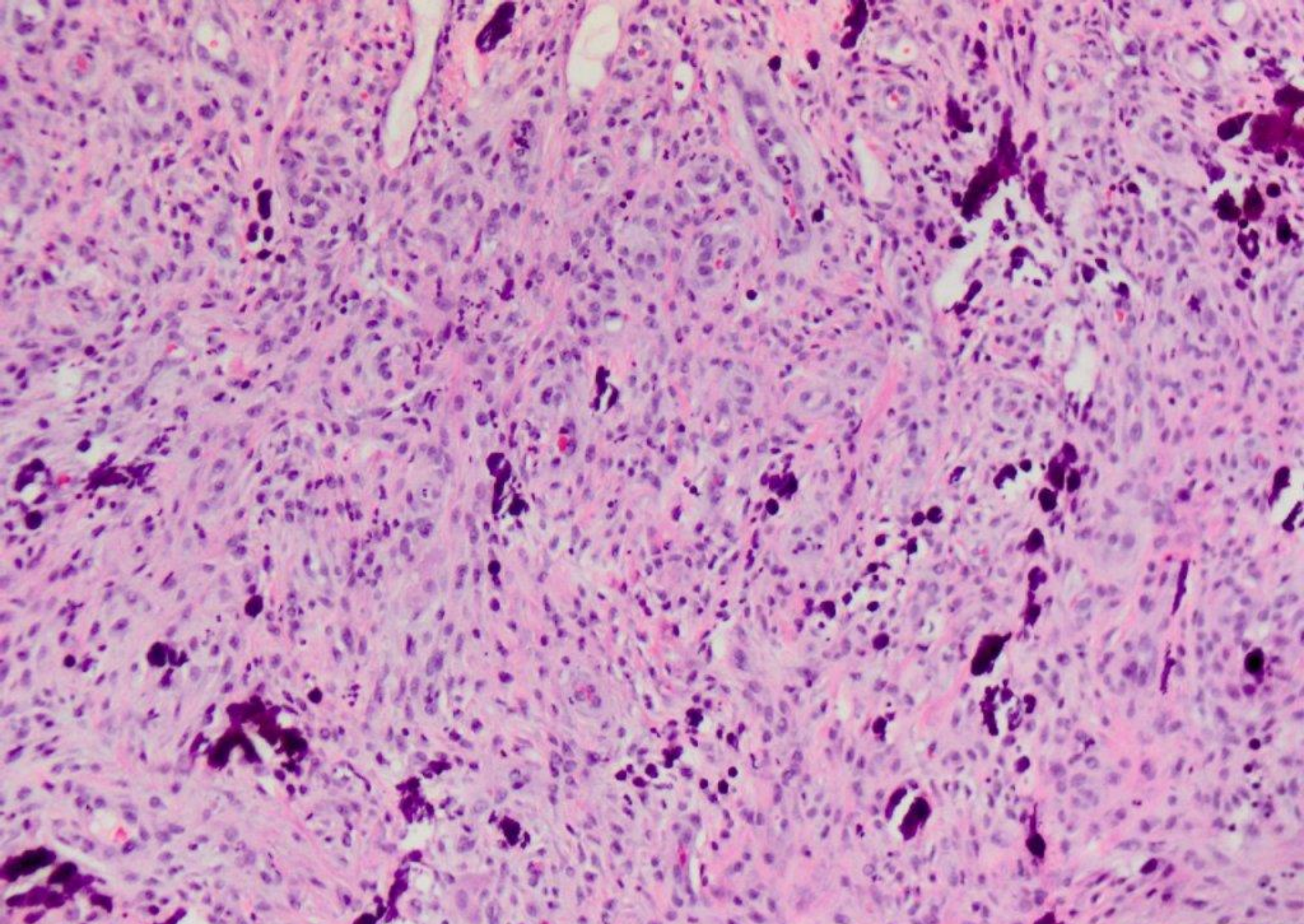




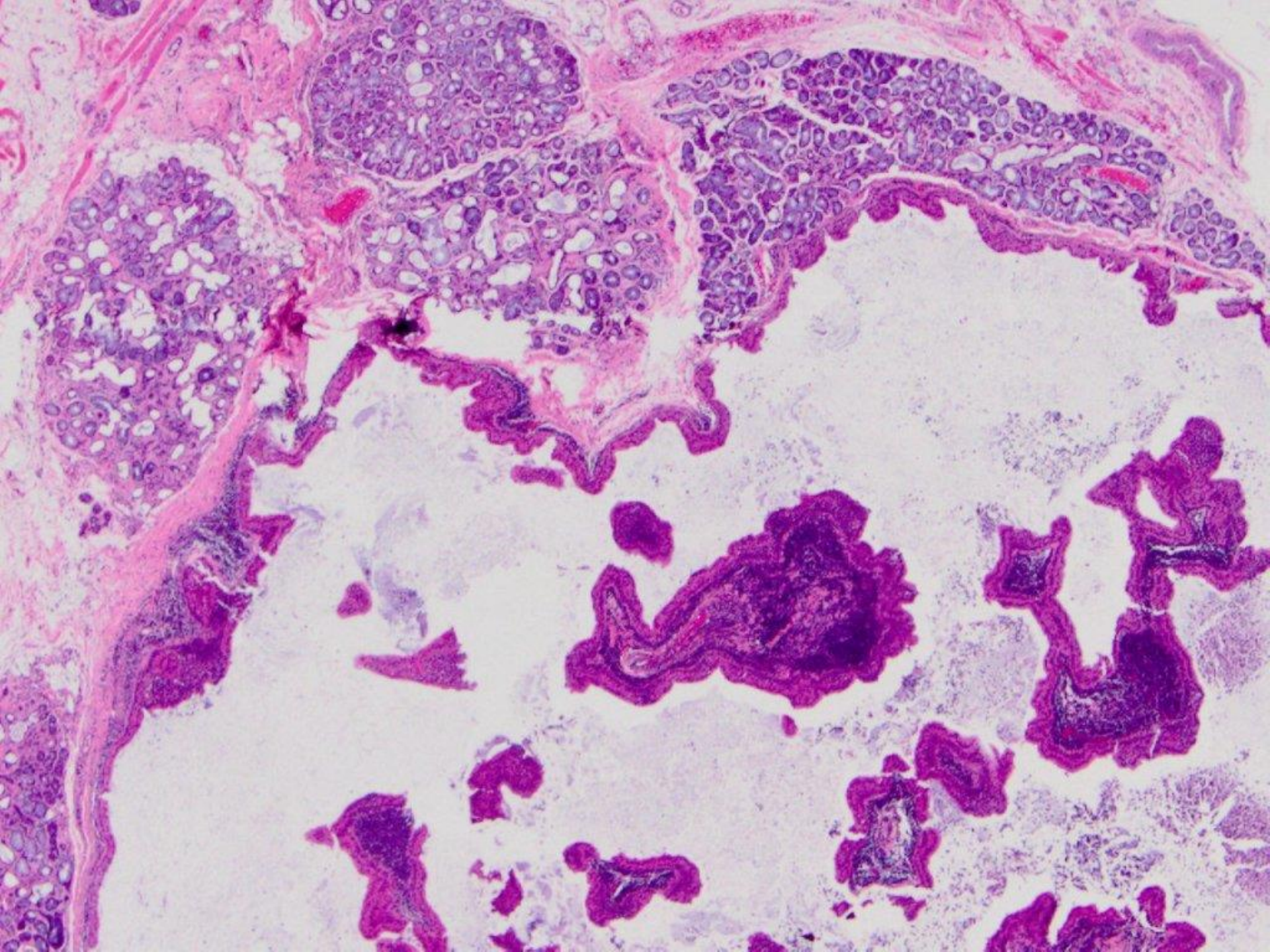
ulcerated pyogenic granuloma

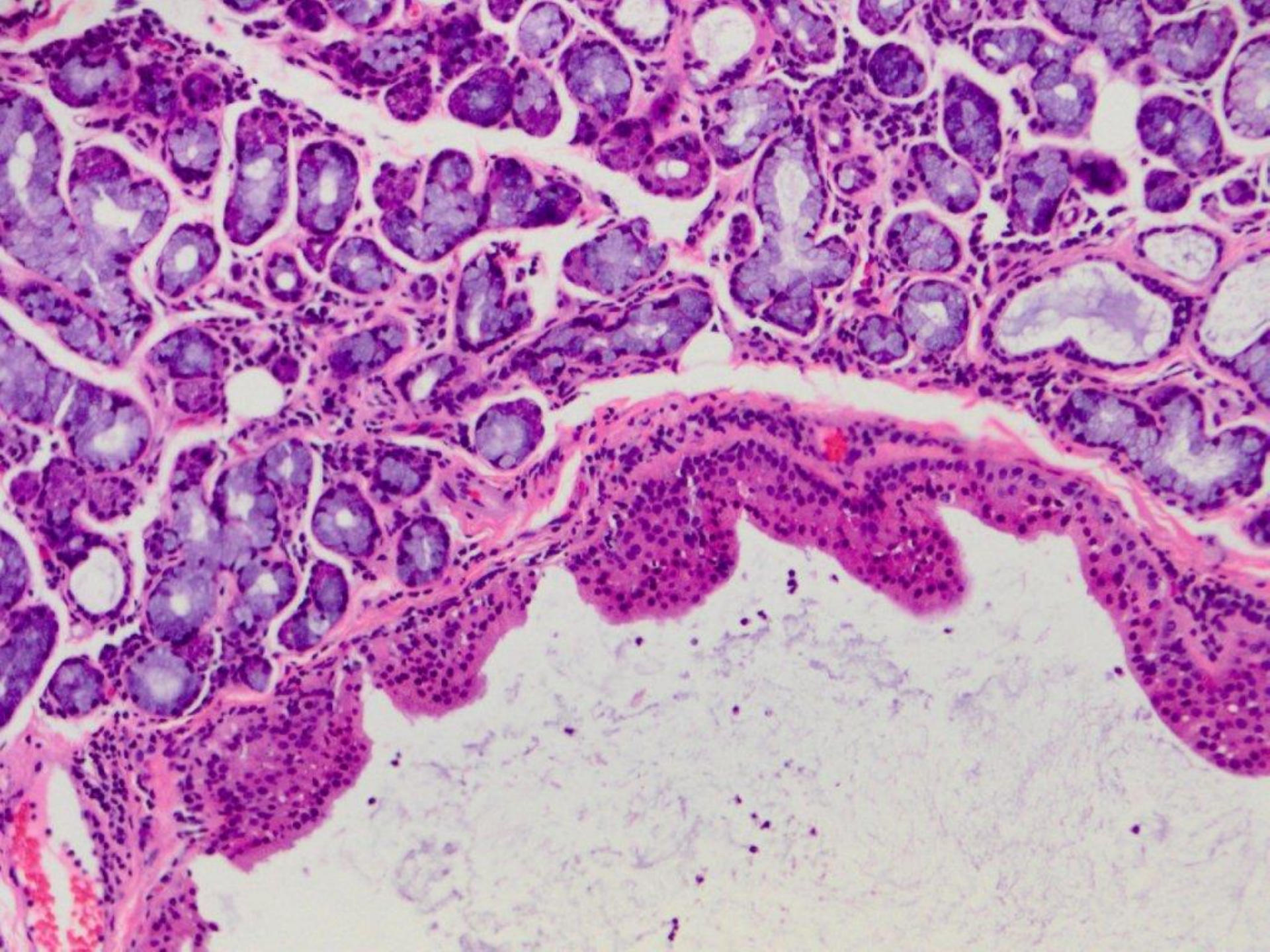


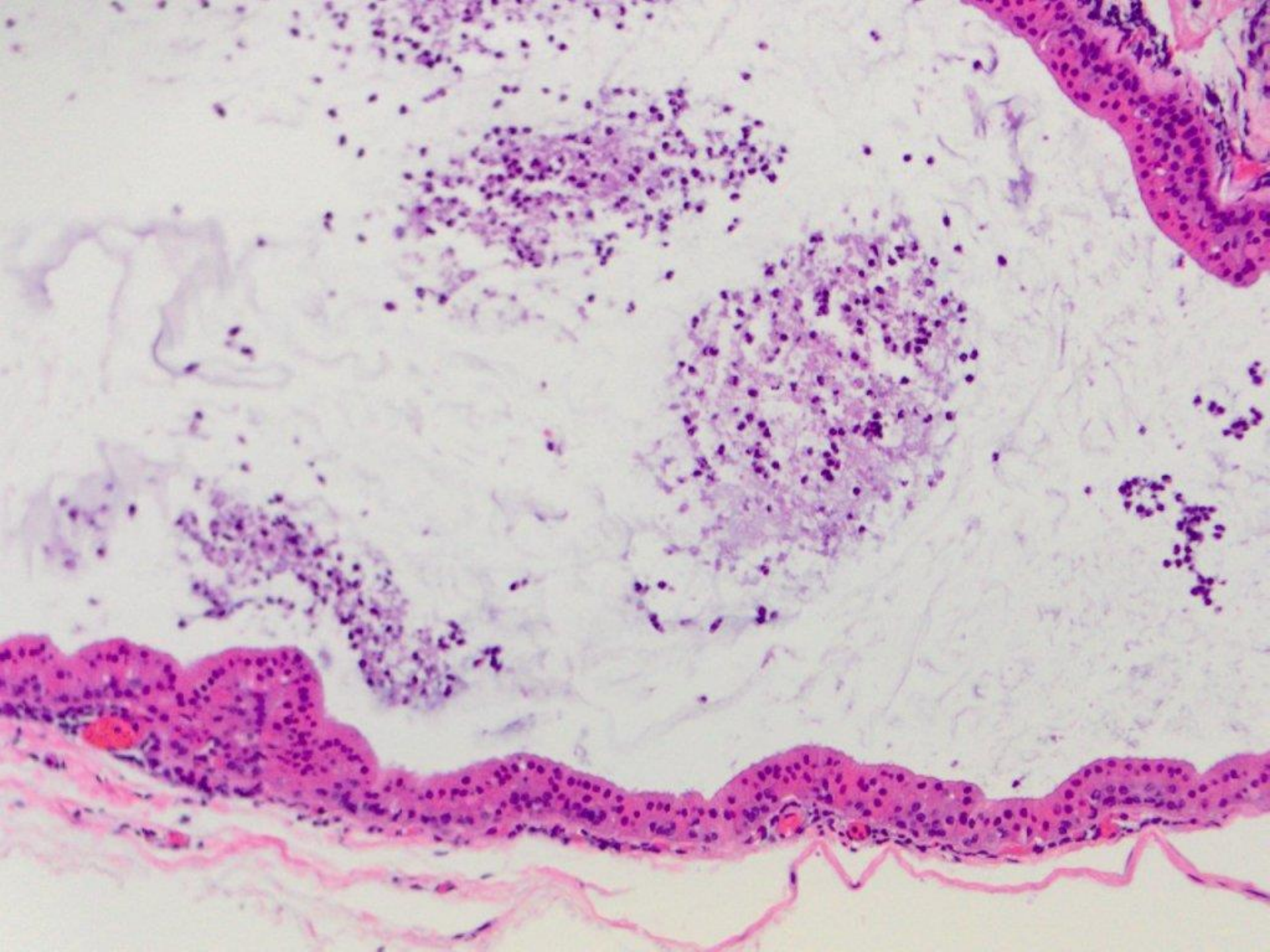


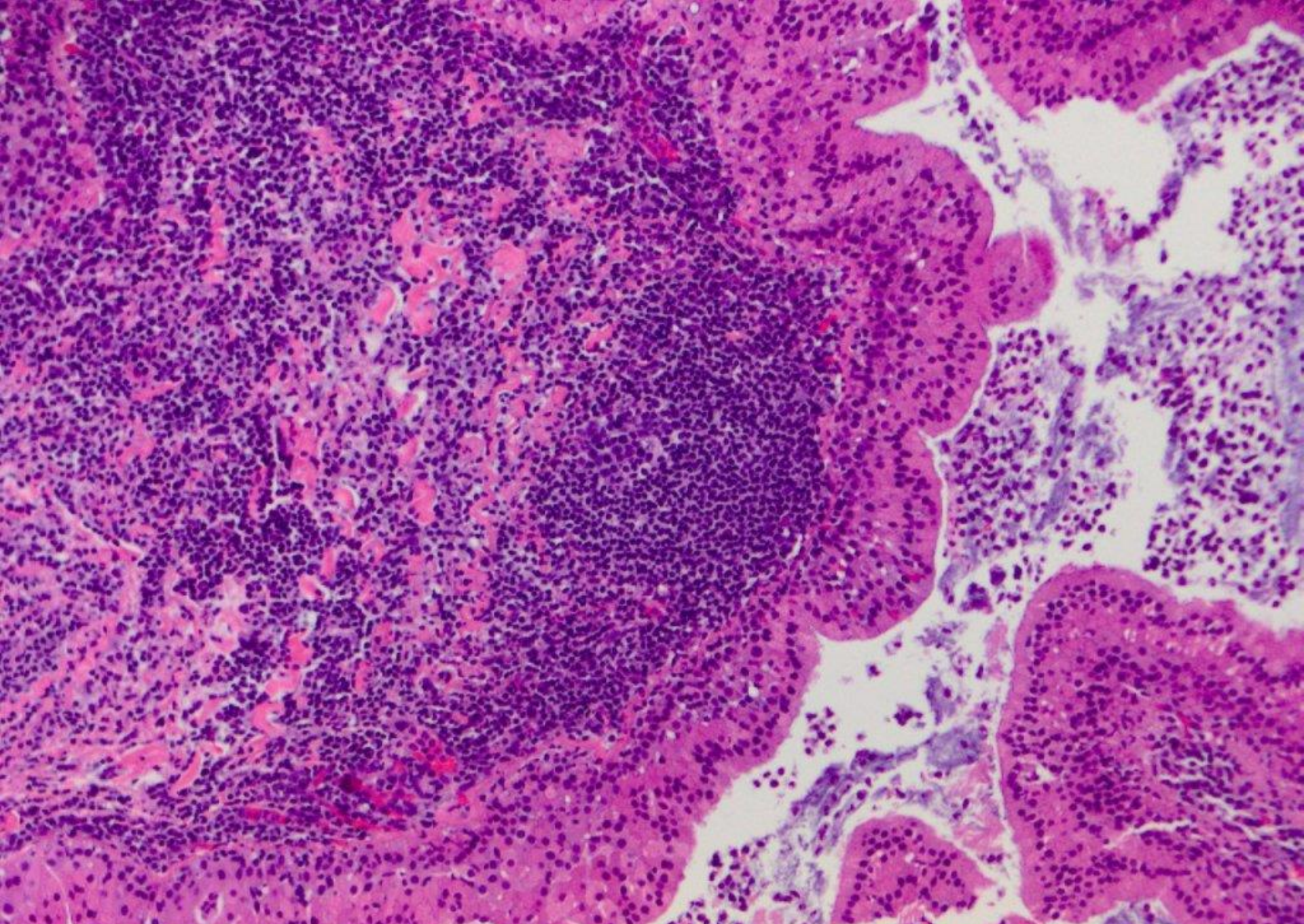


ulcerated peripheral ossifying fibroma

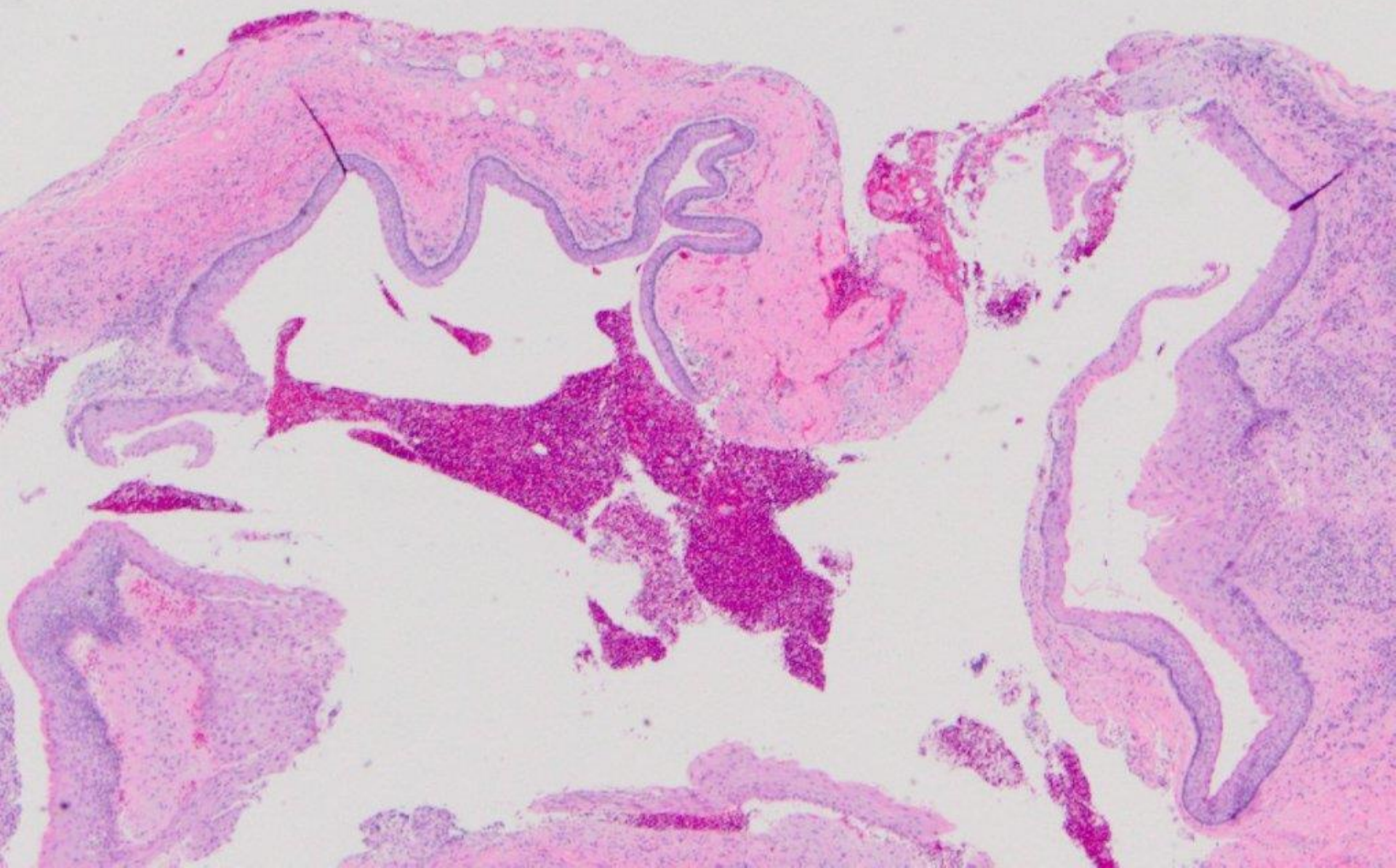


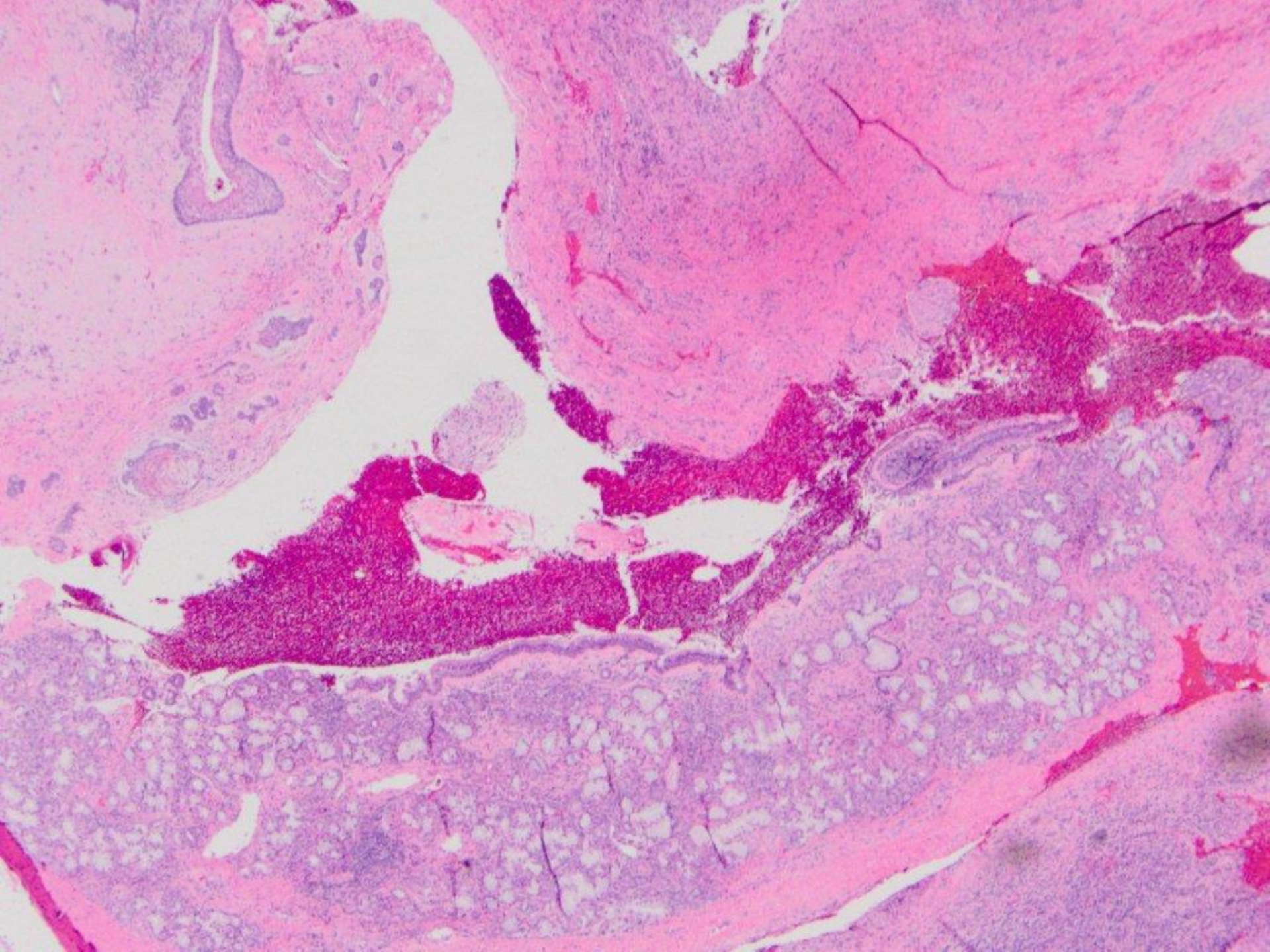


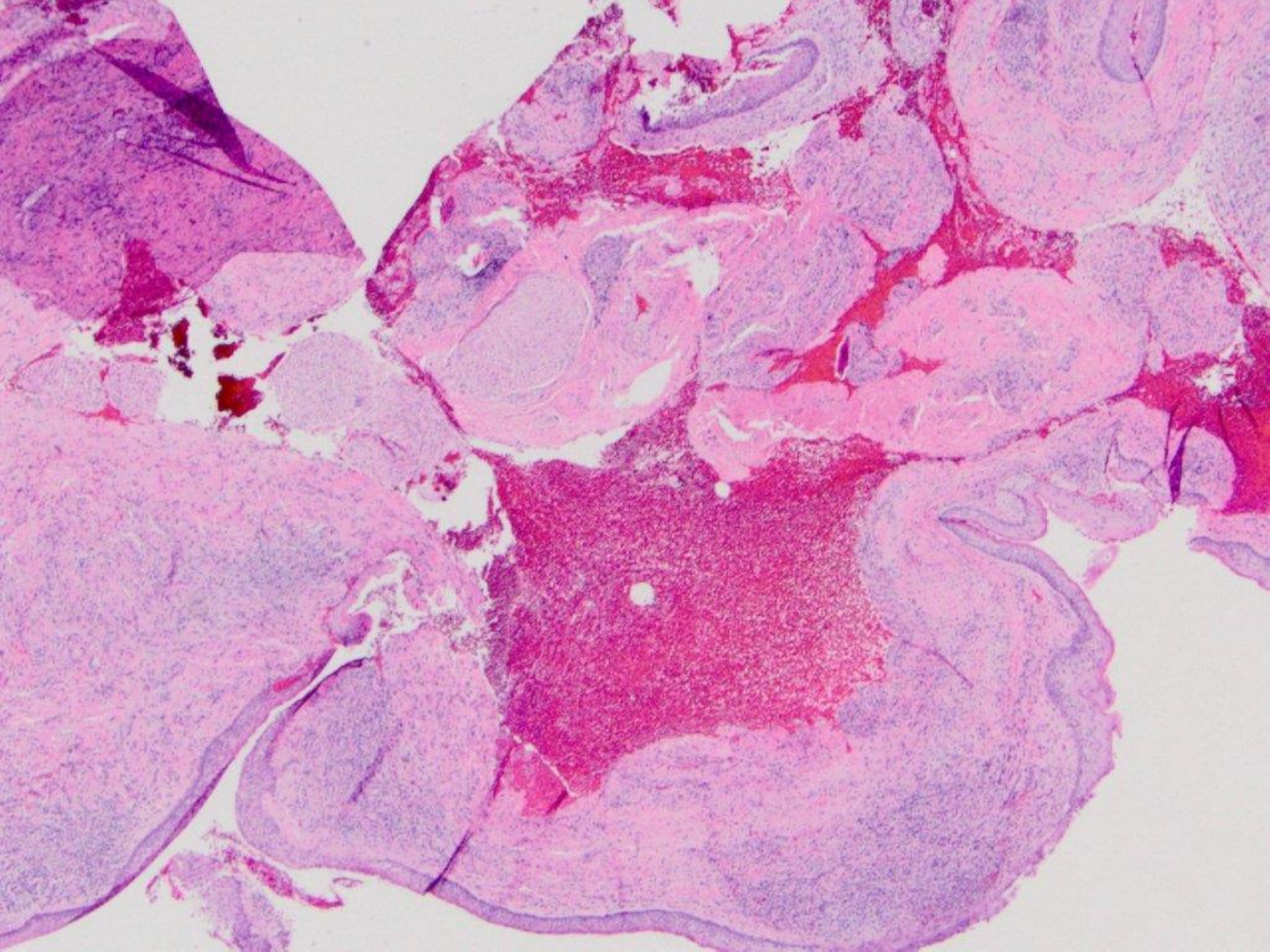


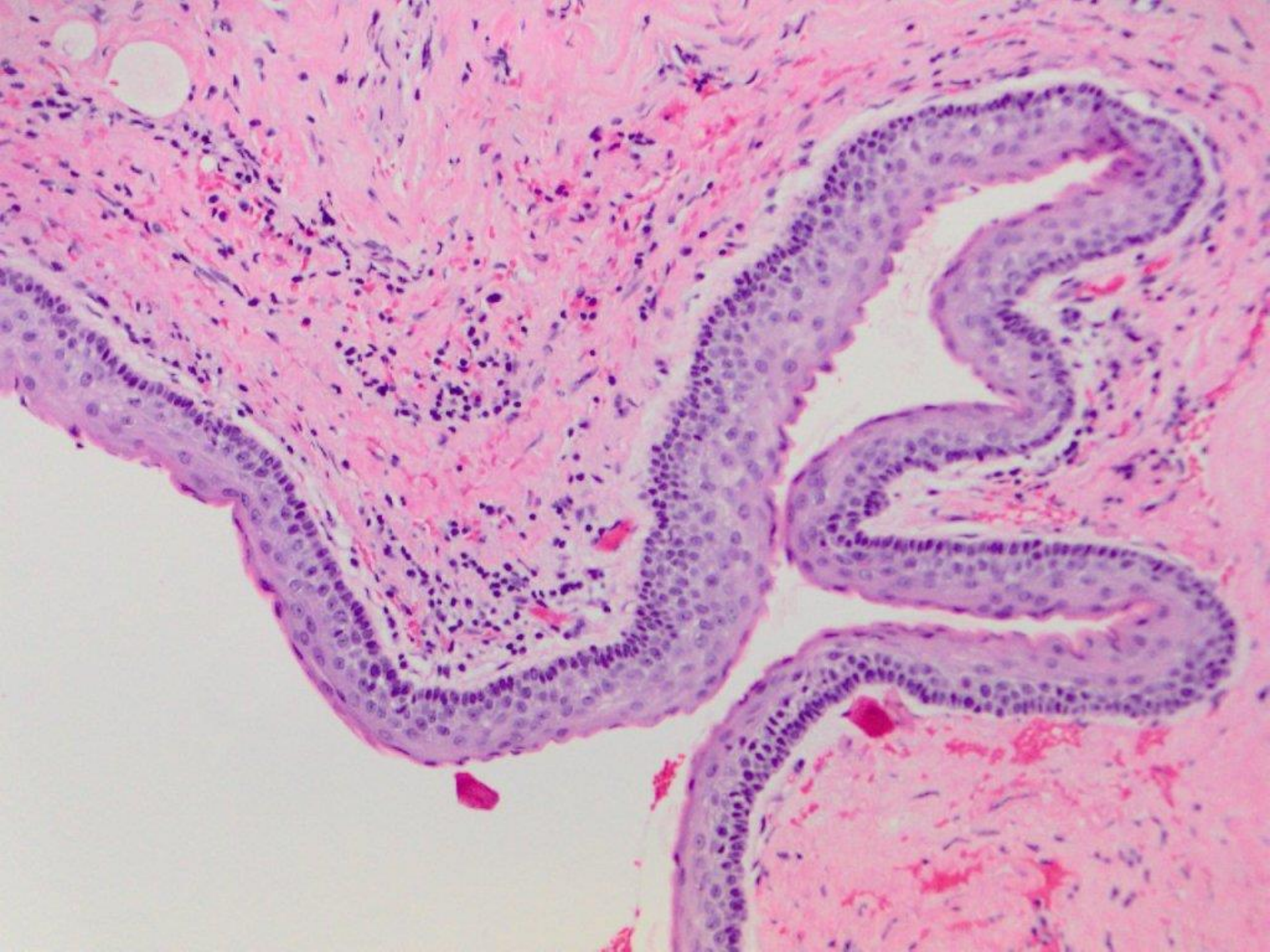


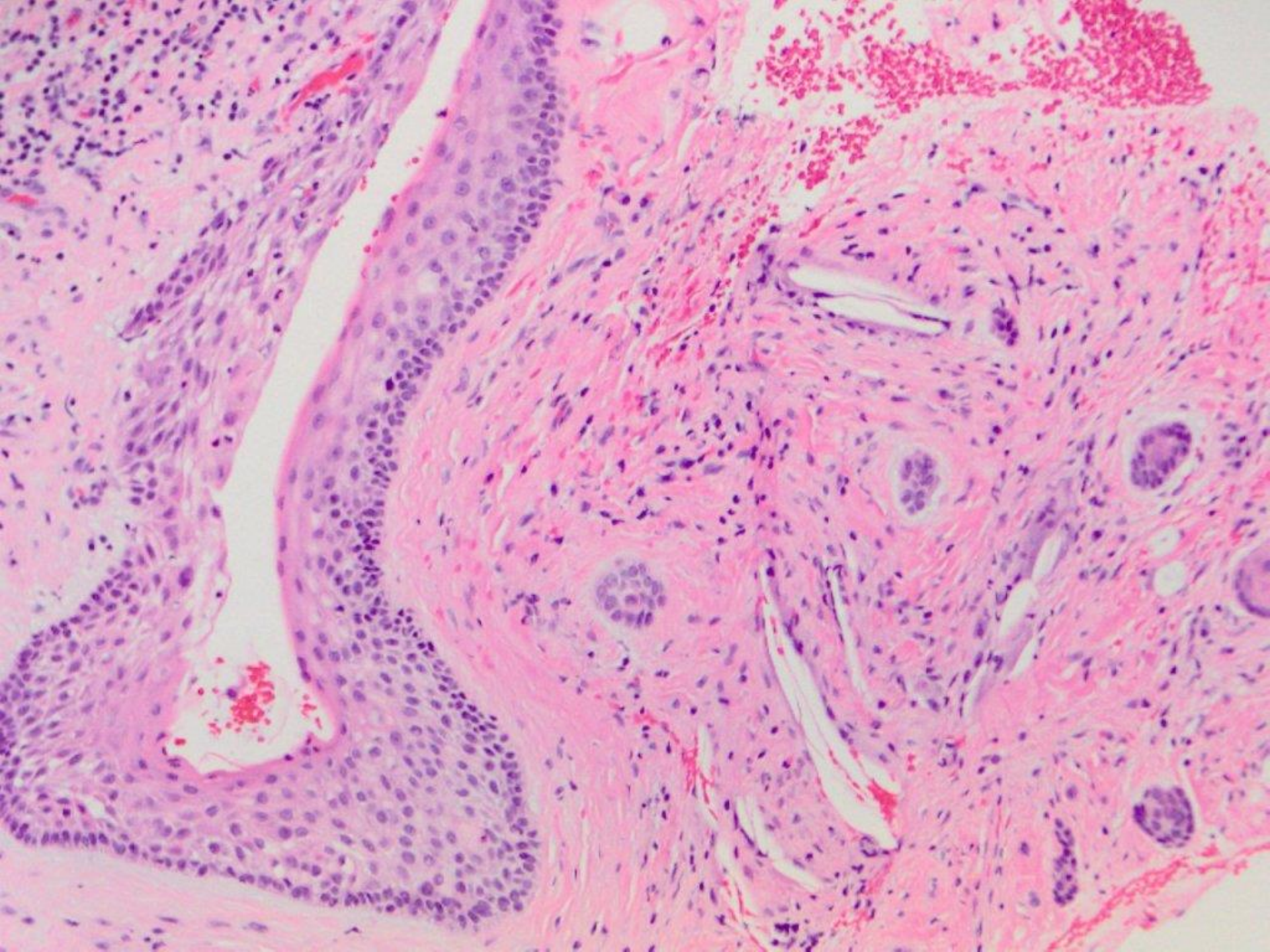
oncocytic papillary cystadenoma with lymphoid stroma

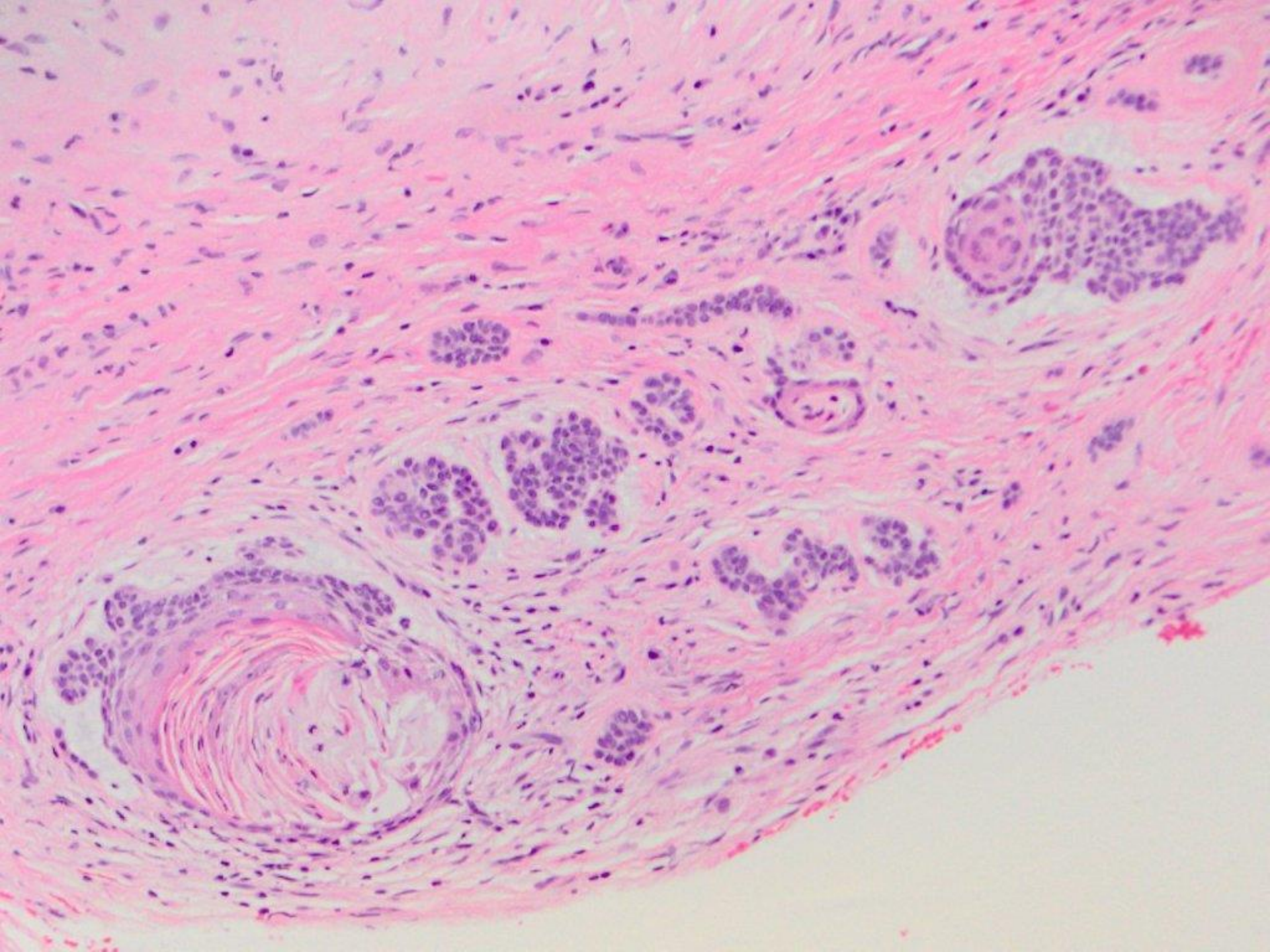


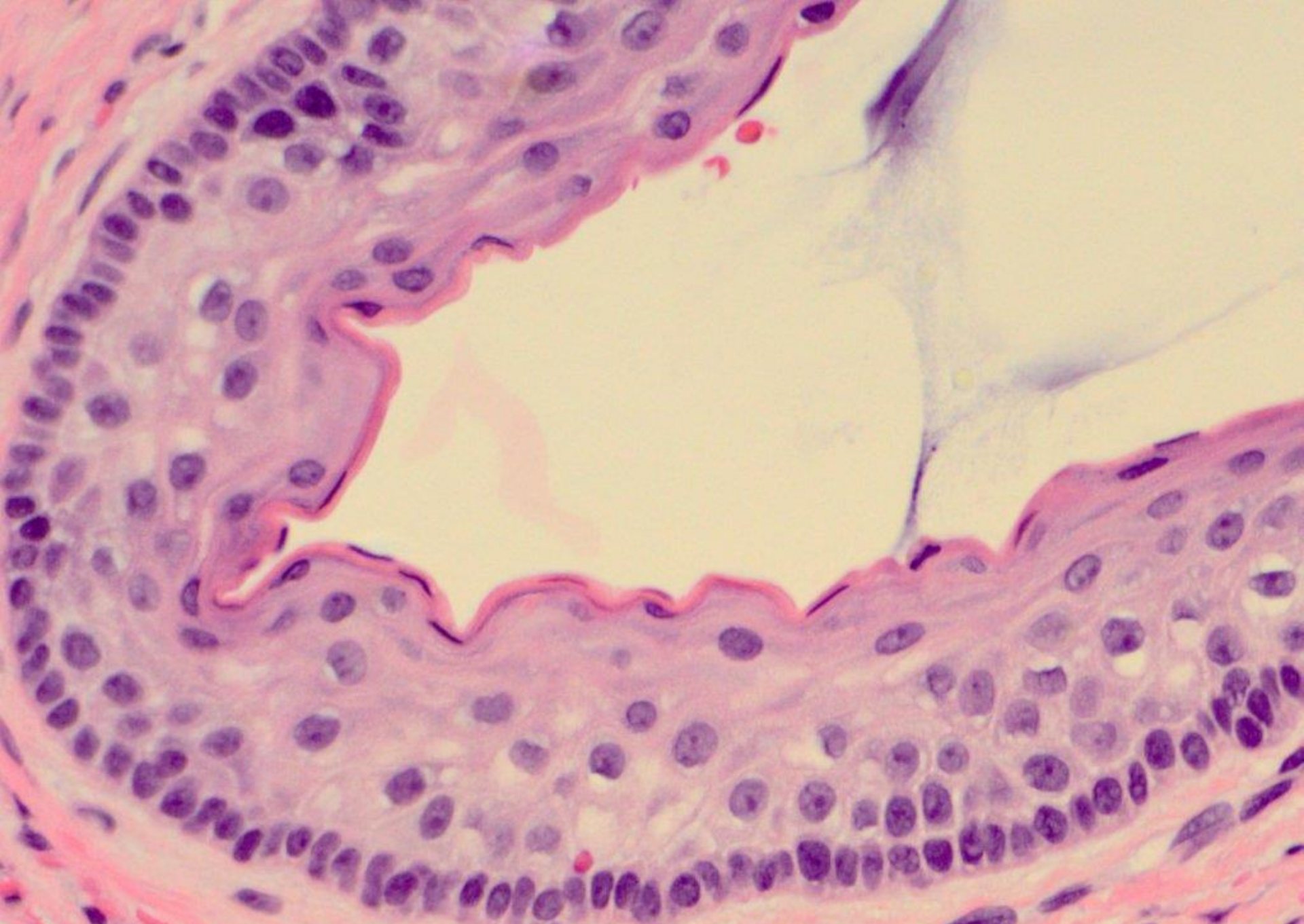




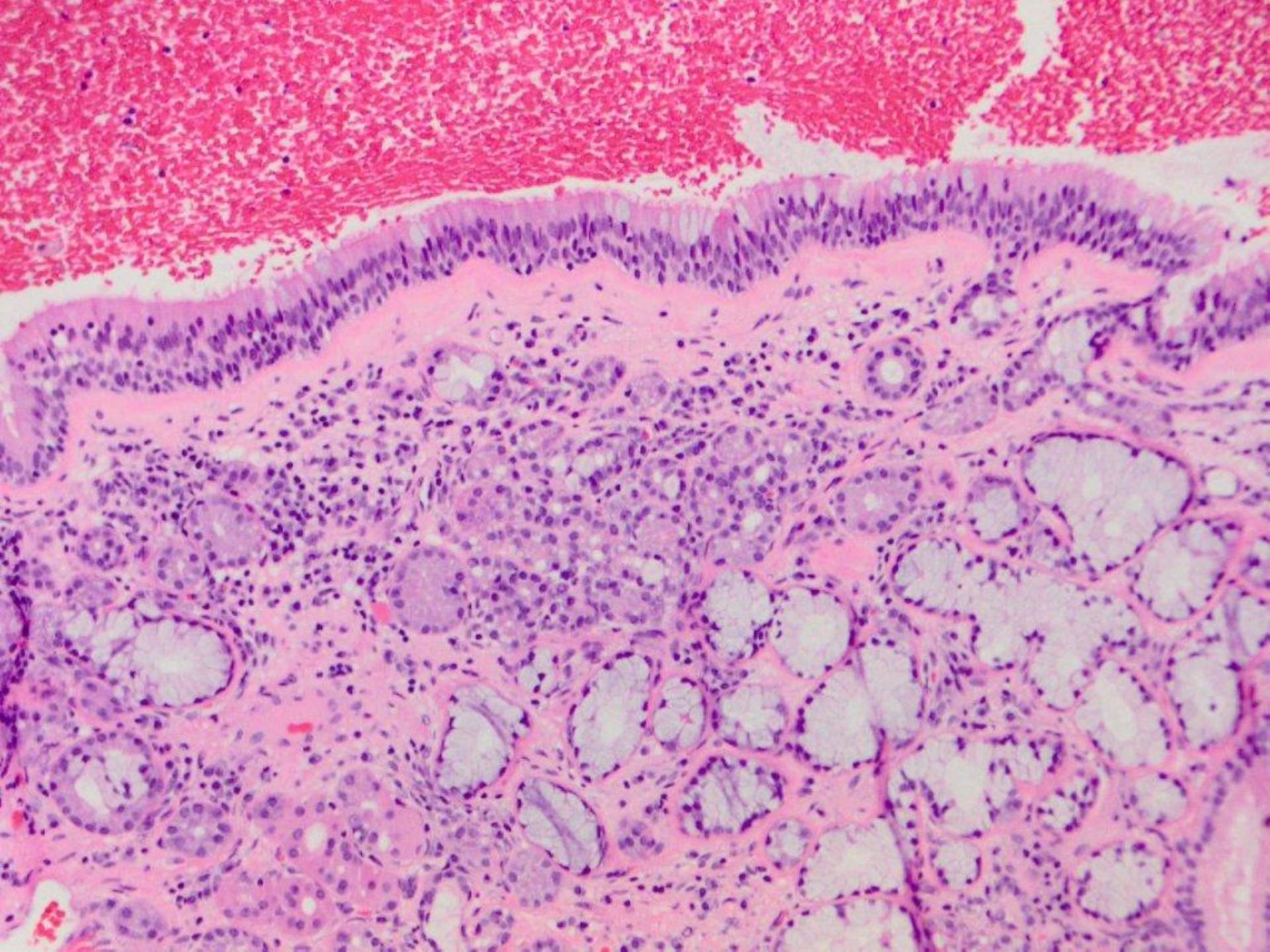


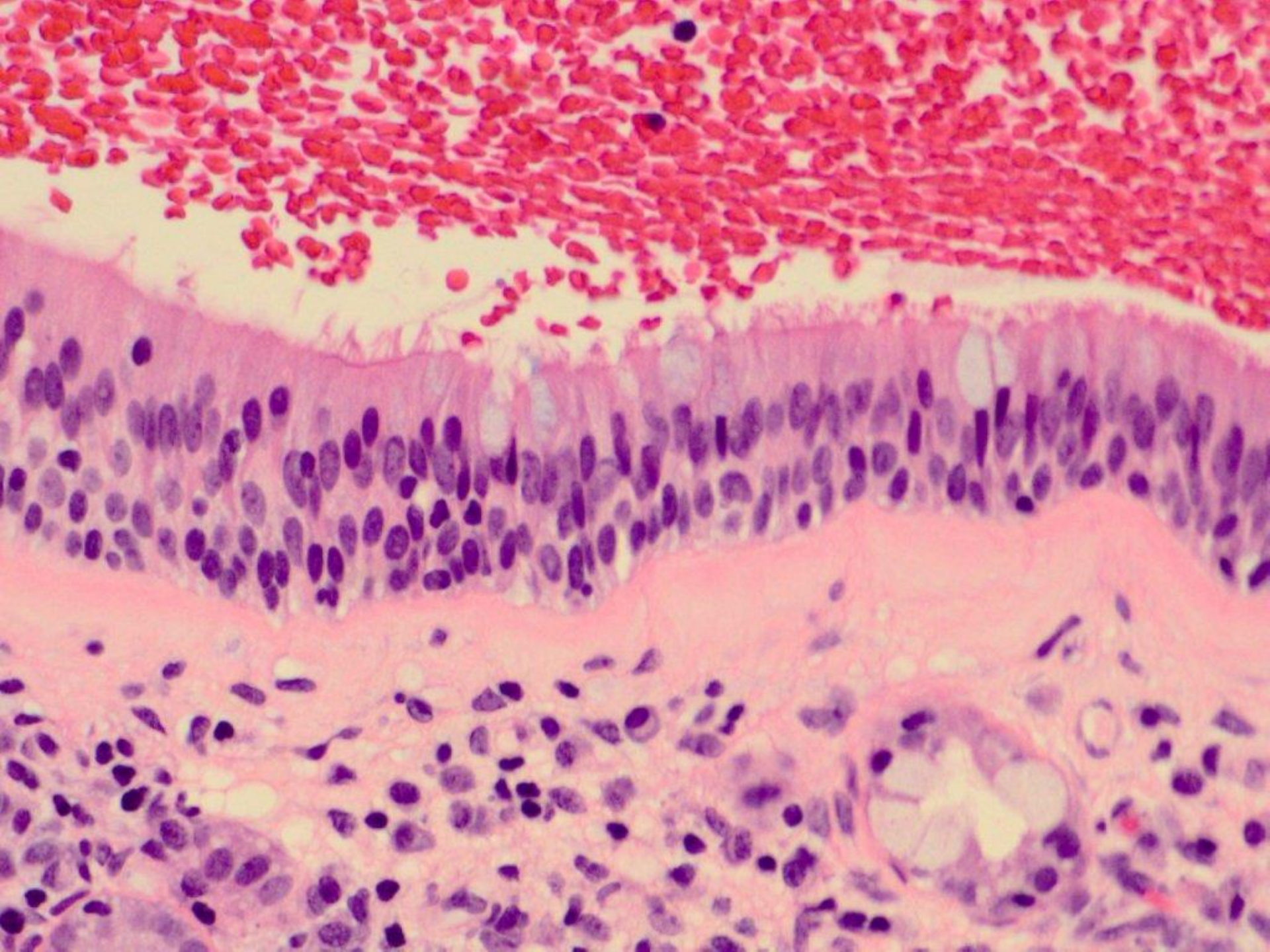


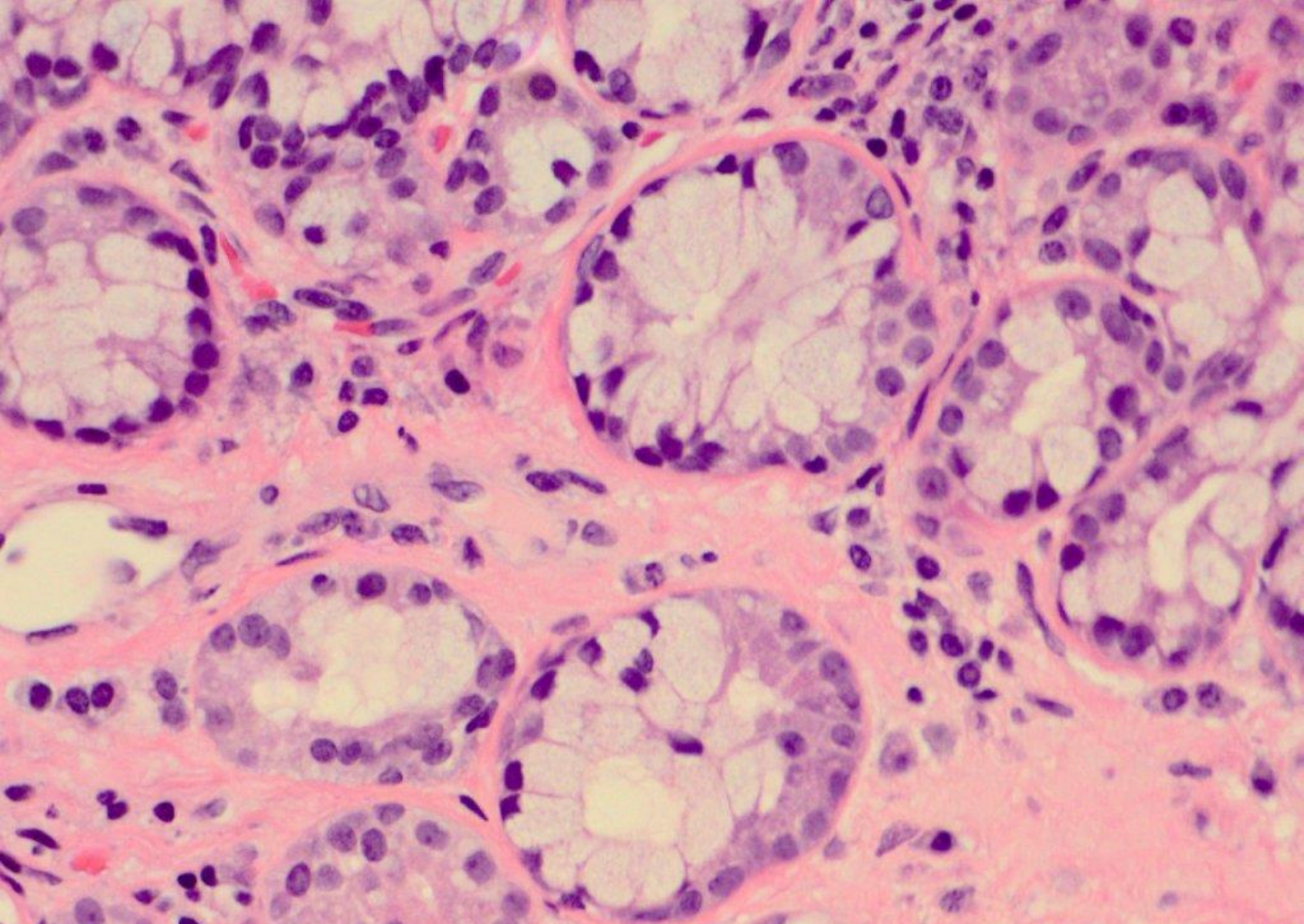




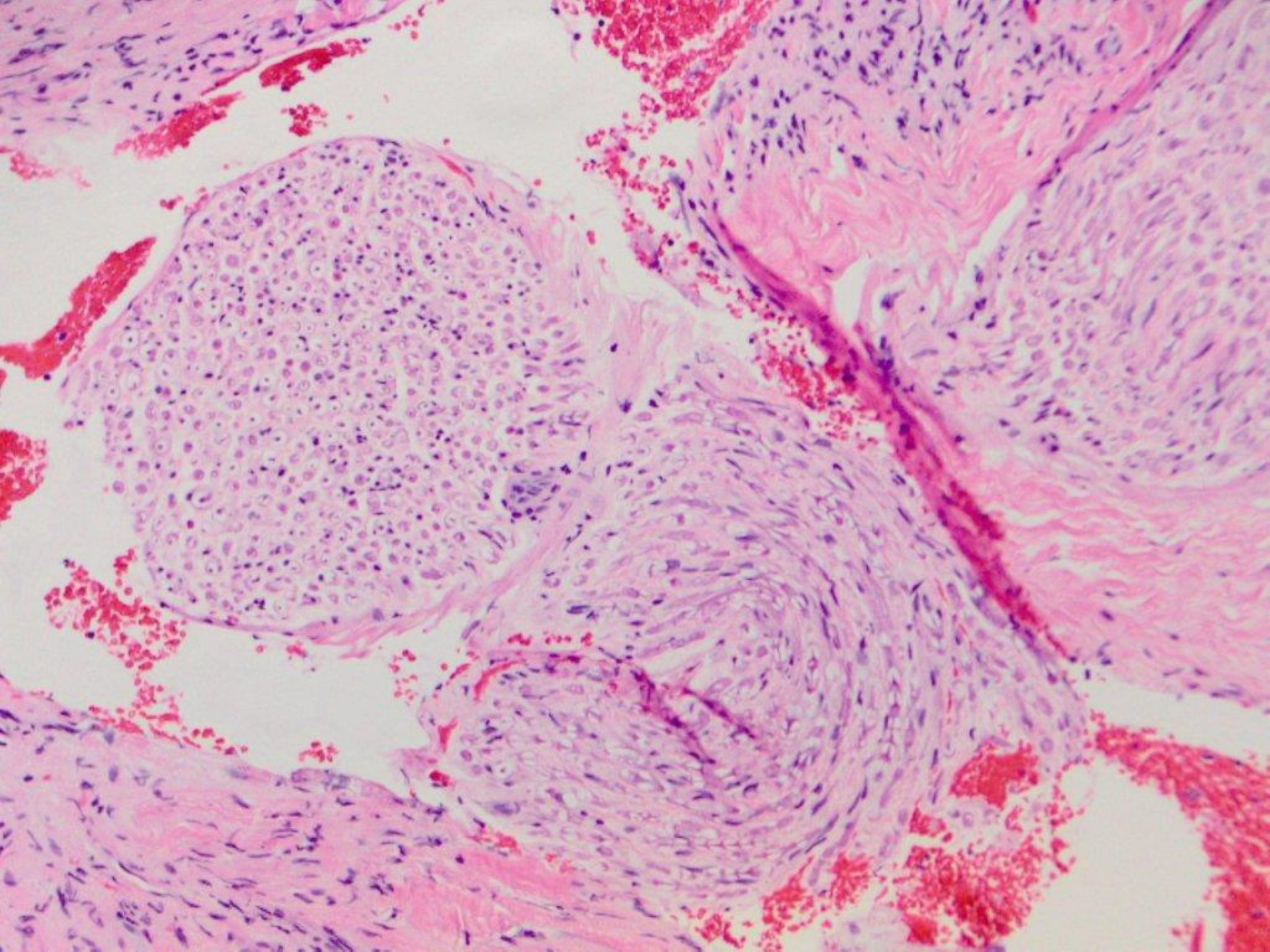
odontogenic keratocyst (keratocystic odontogenic tumor)

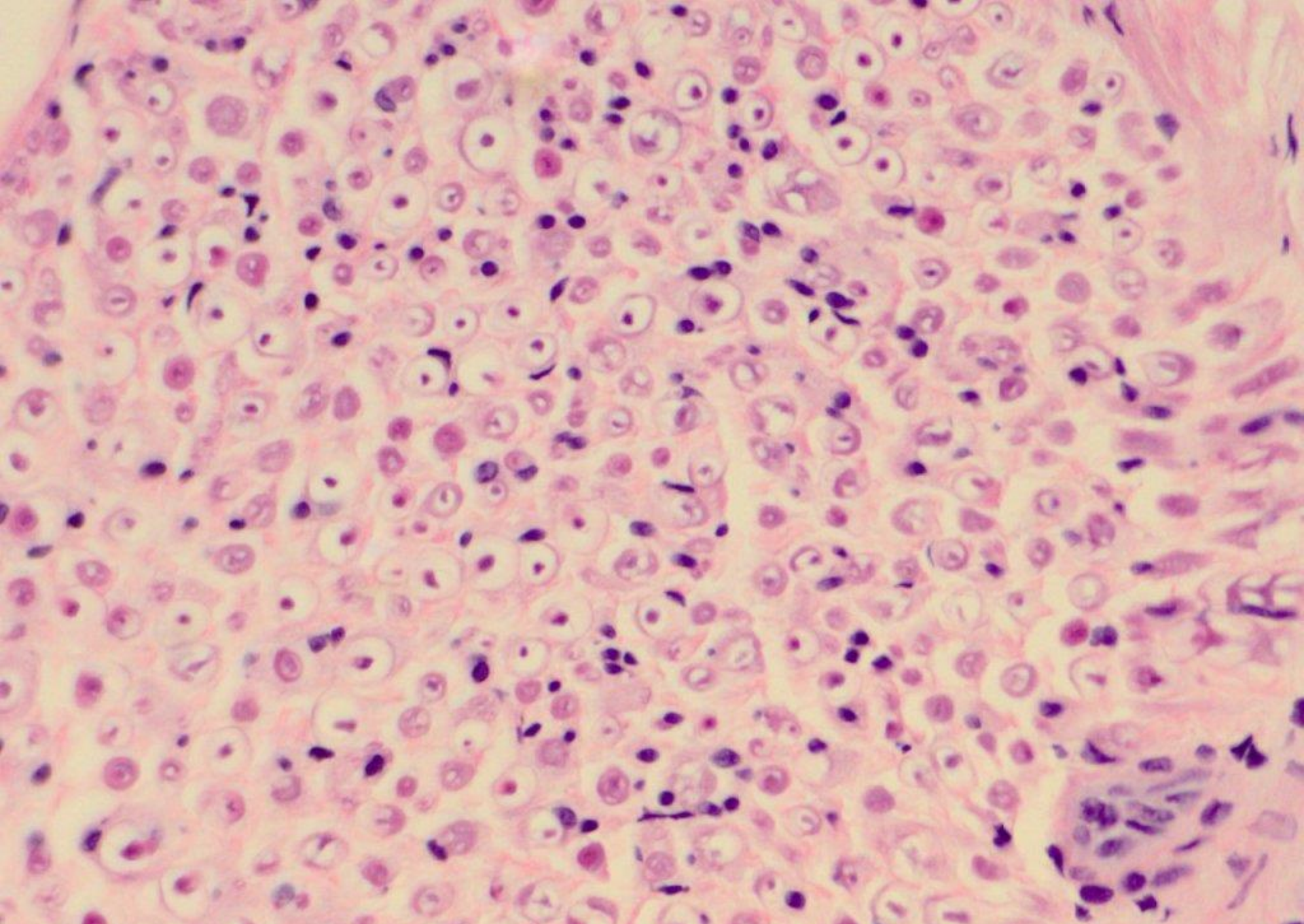




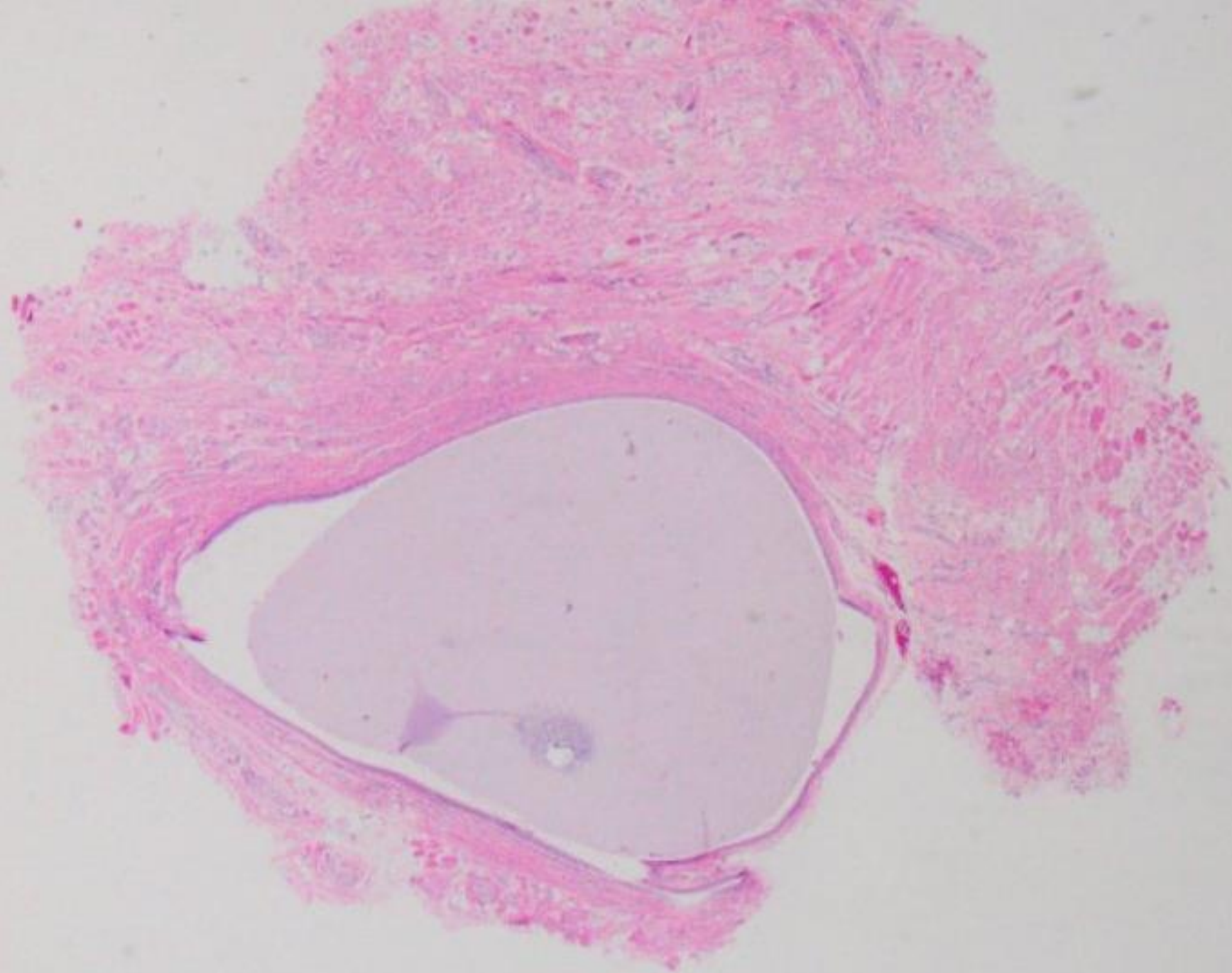


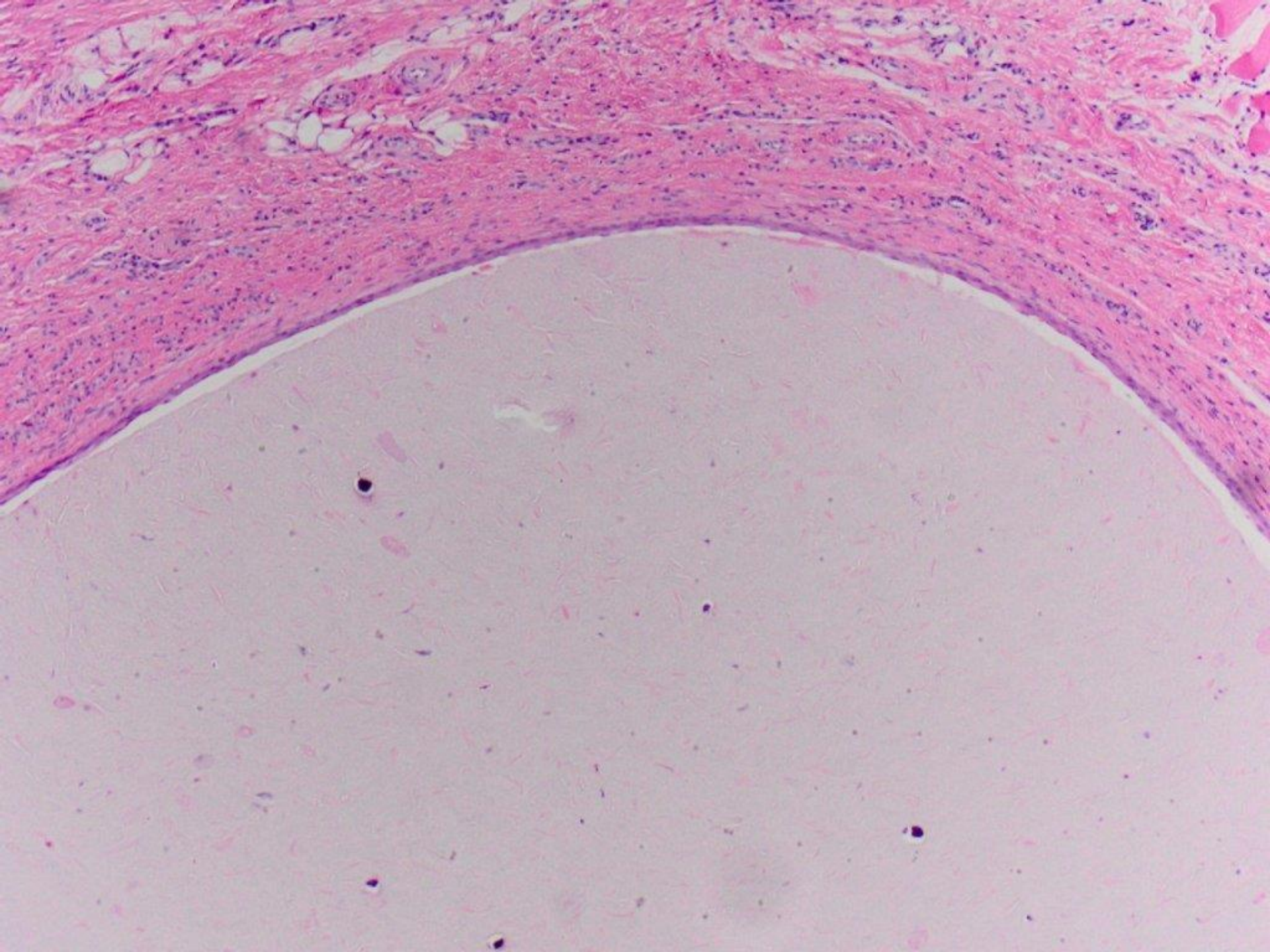
respiratory mucosa and minor glands

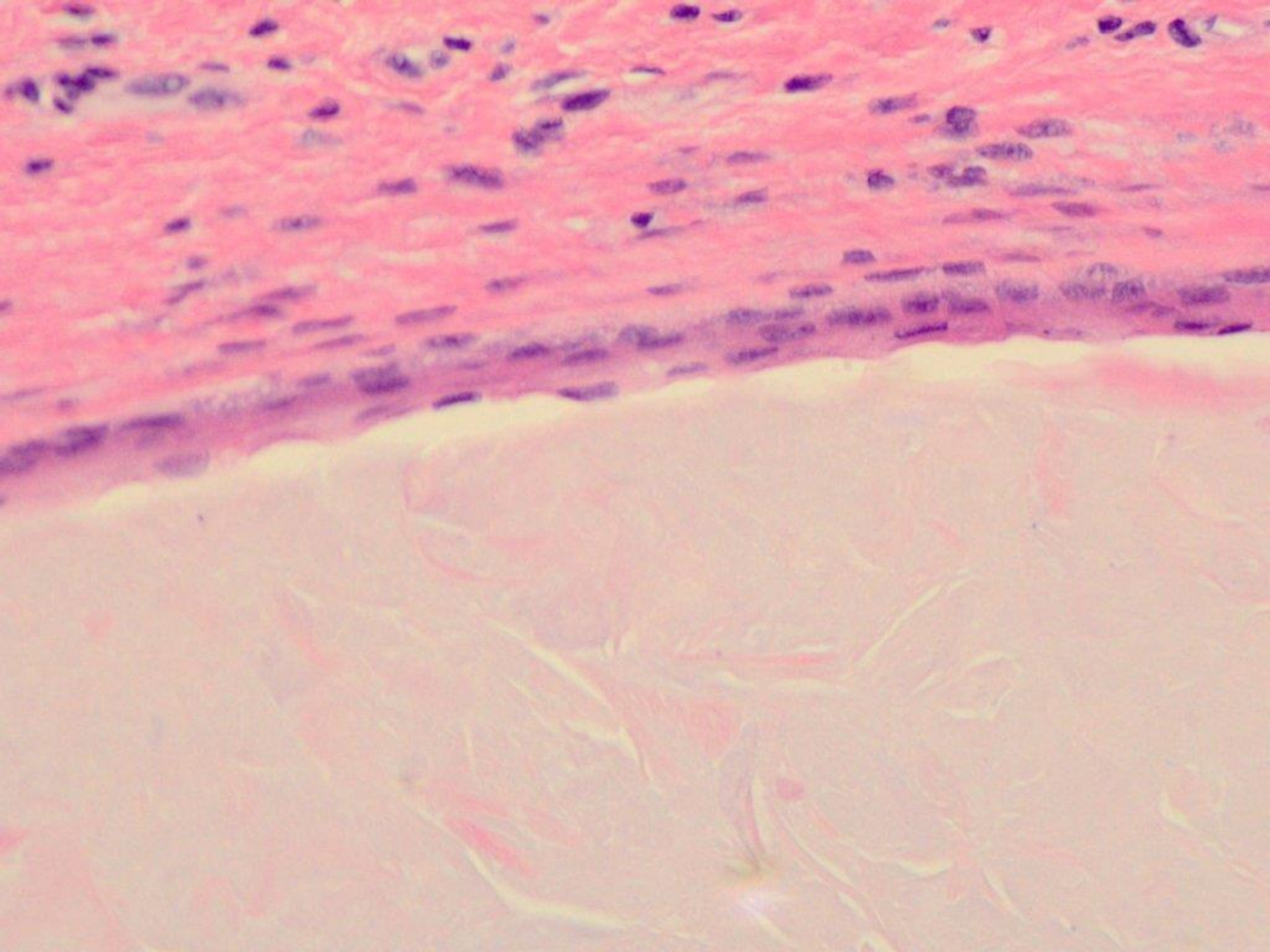


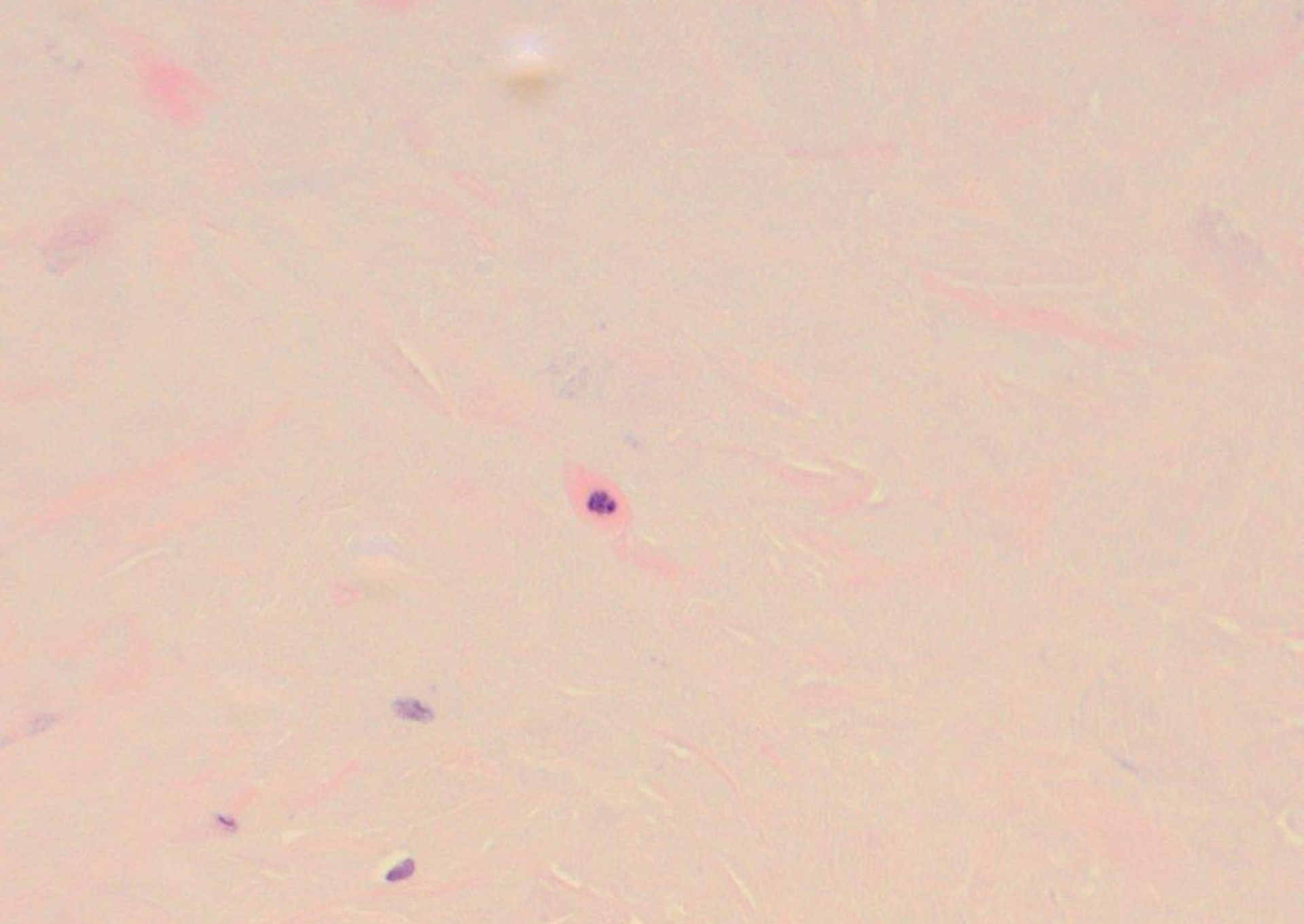


nerve

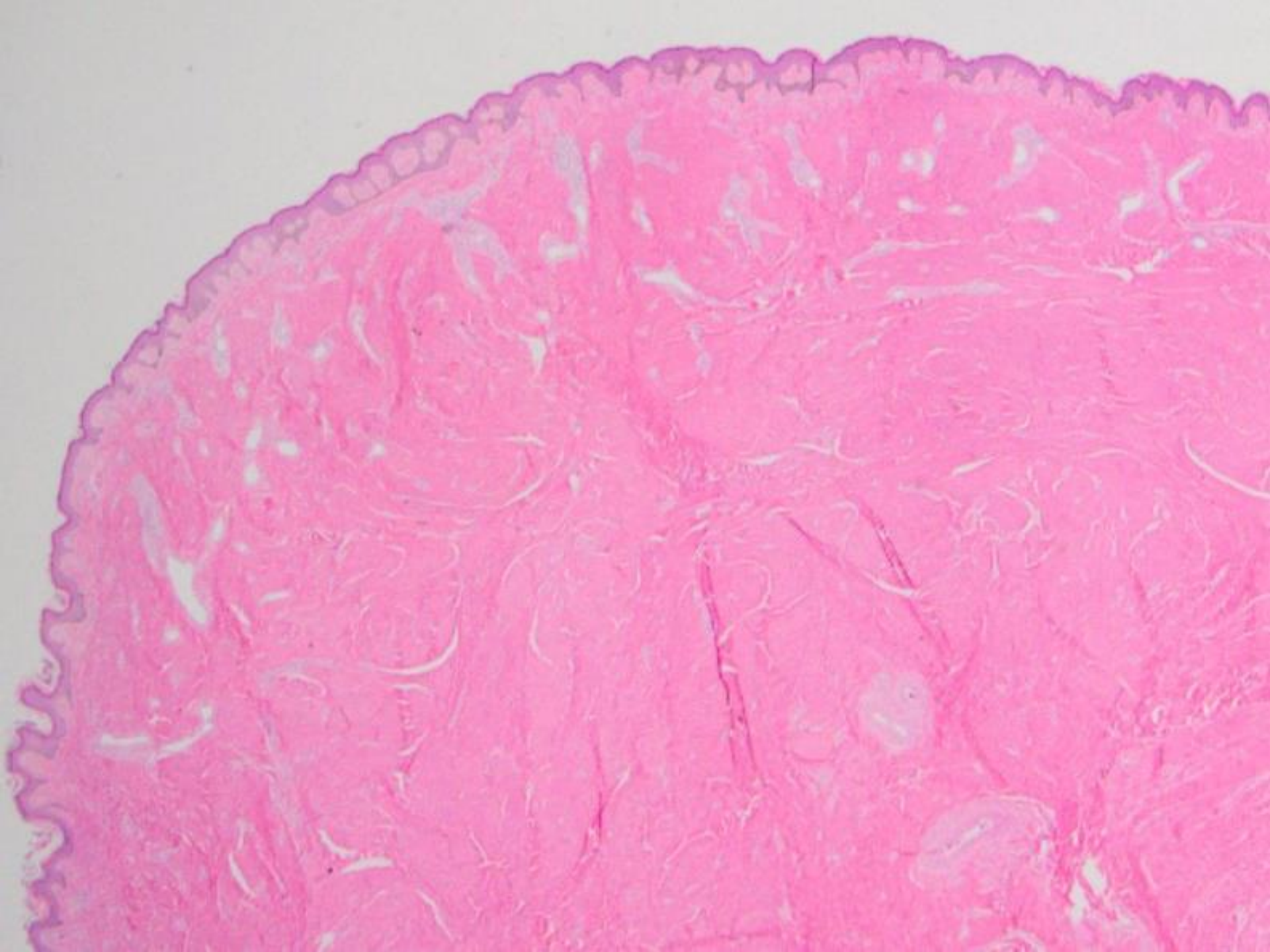


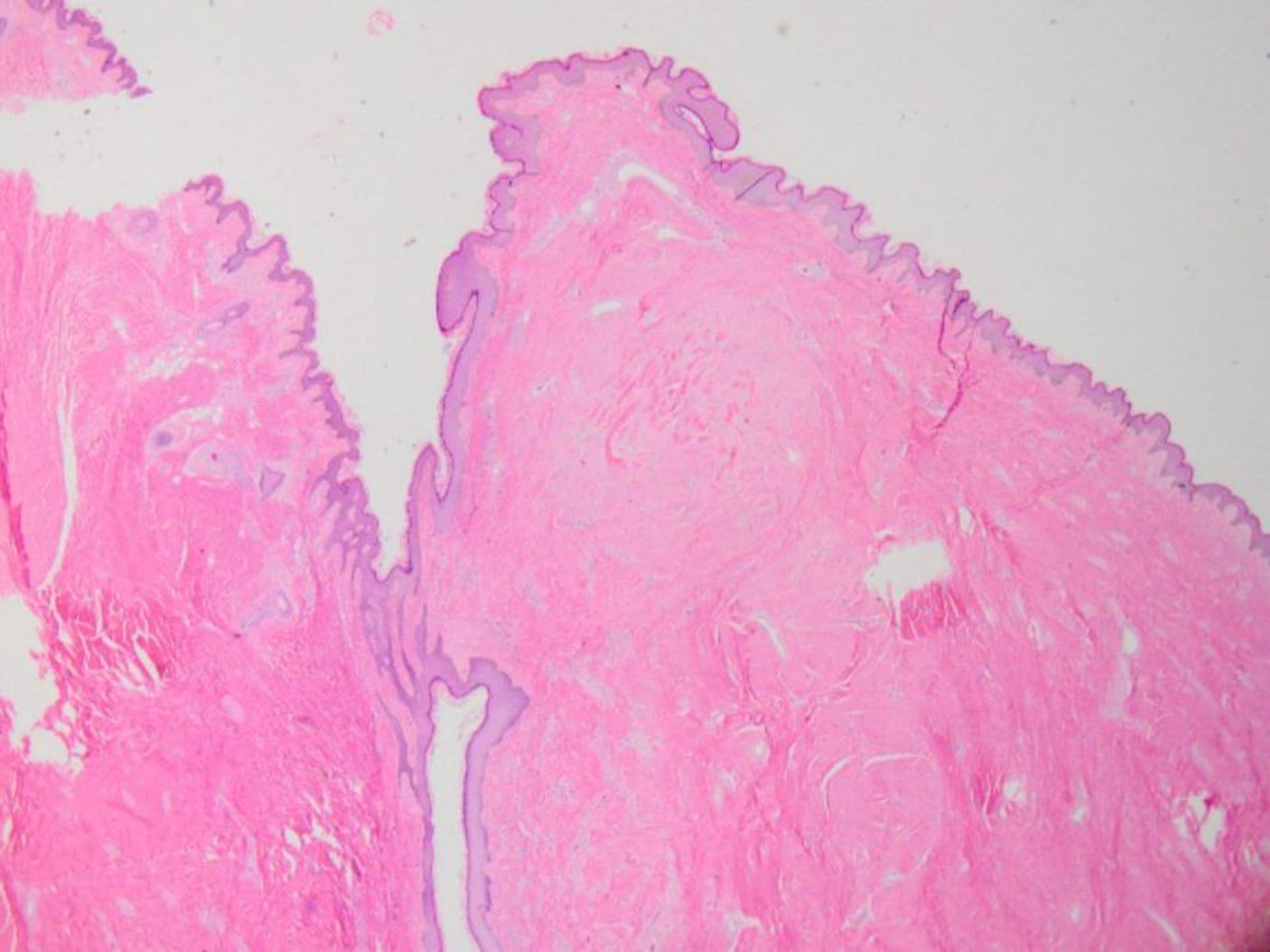


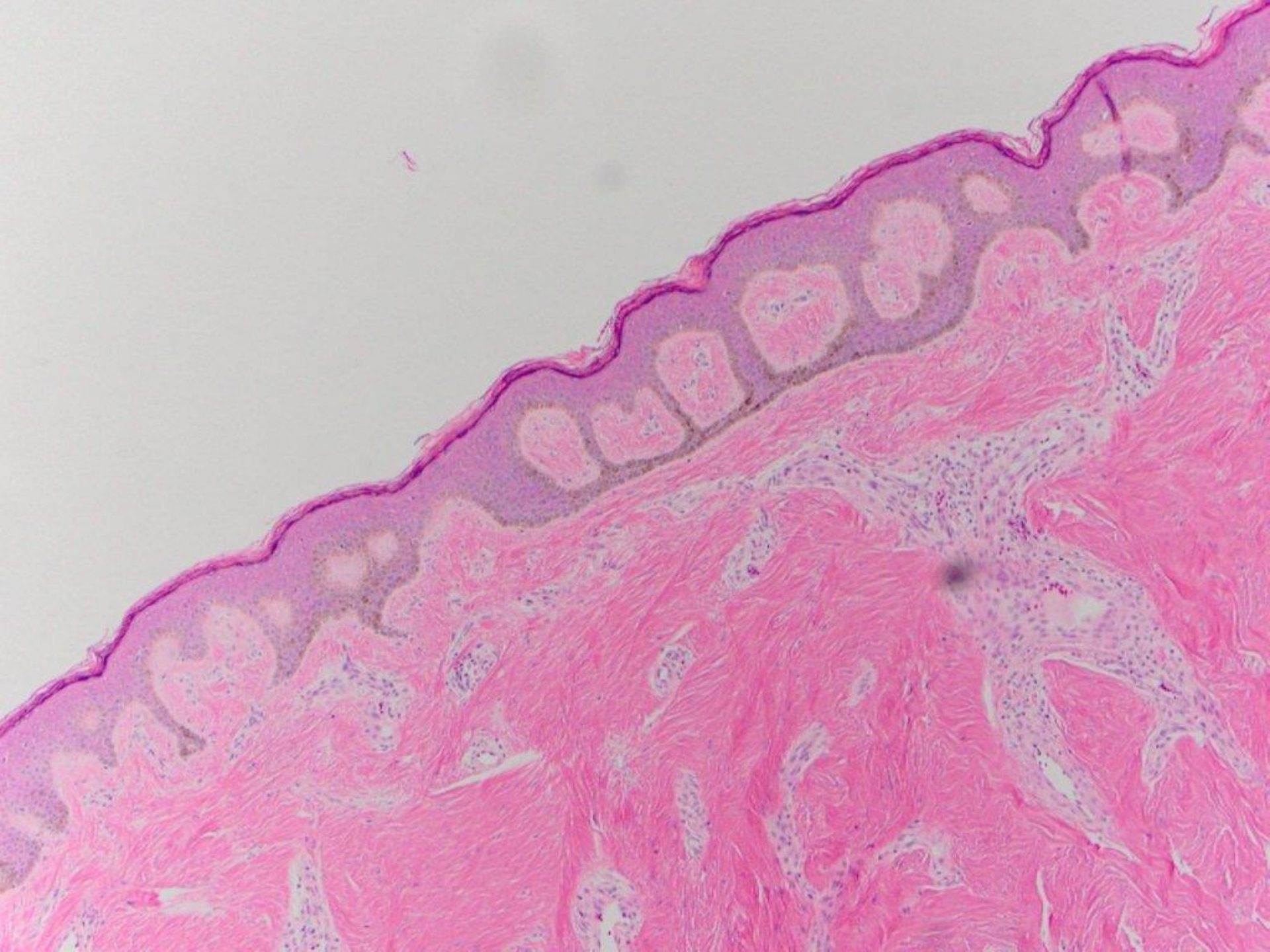

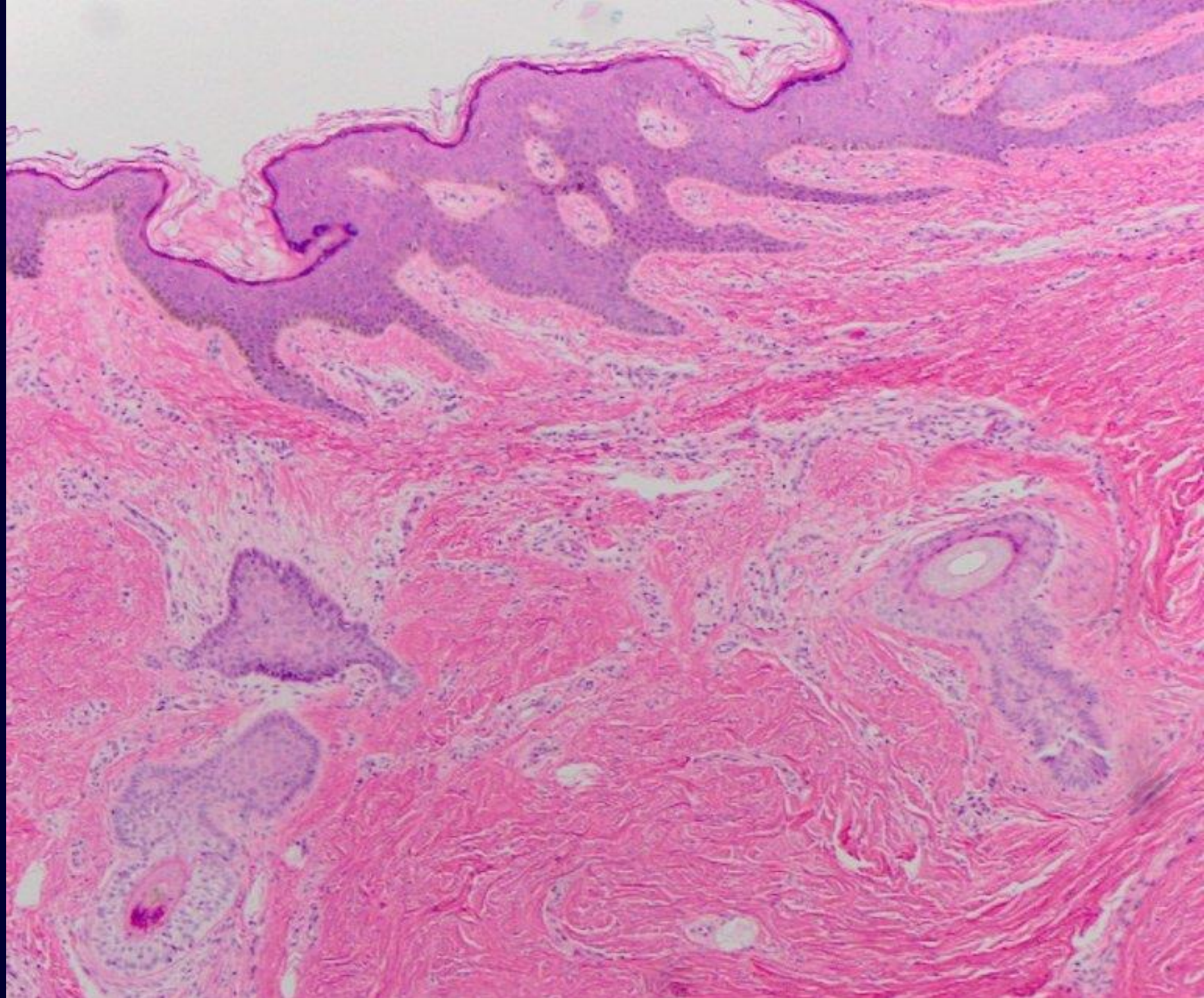


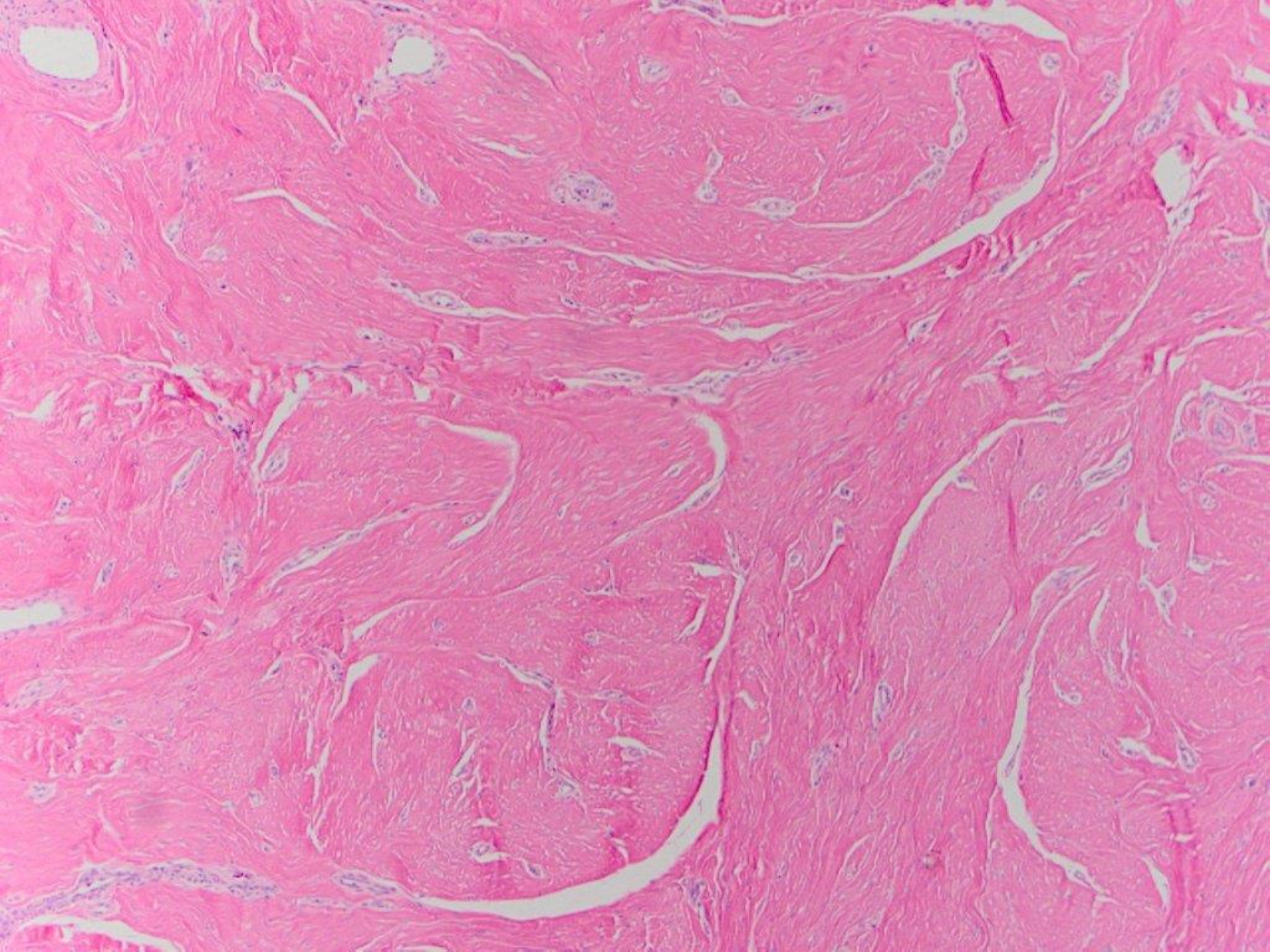
epidermoid (epithelial inclusion) cyst

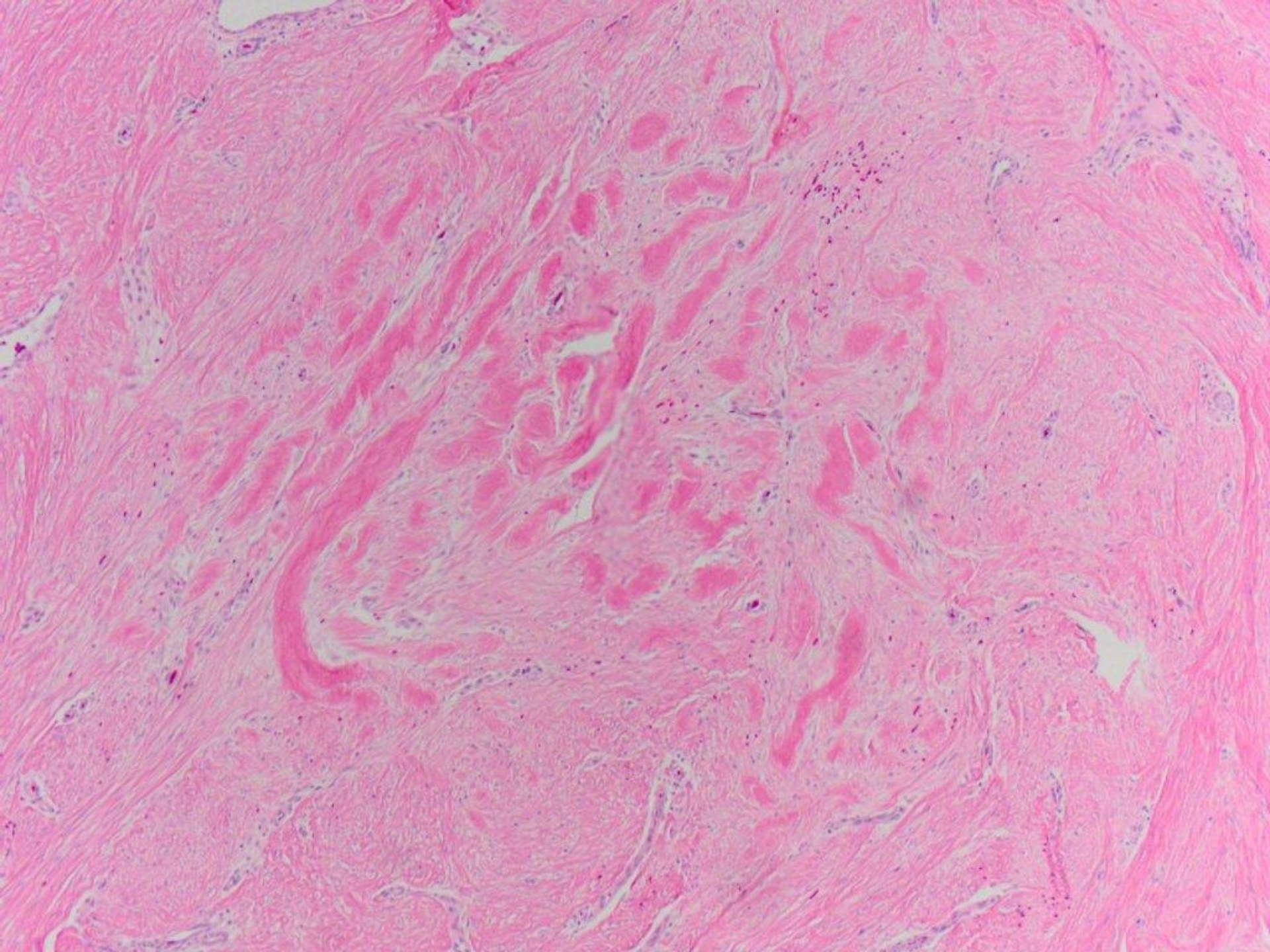


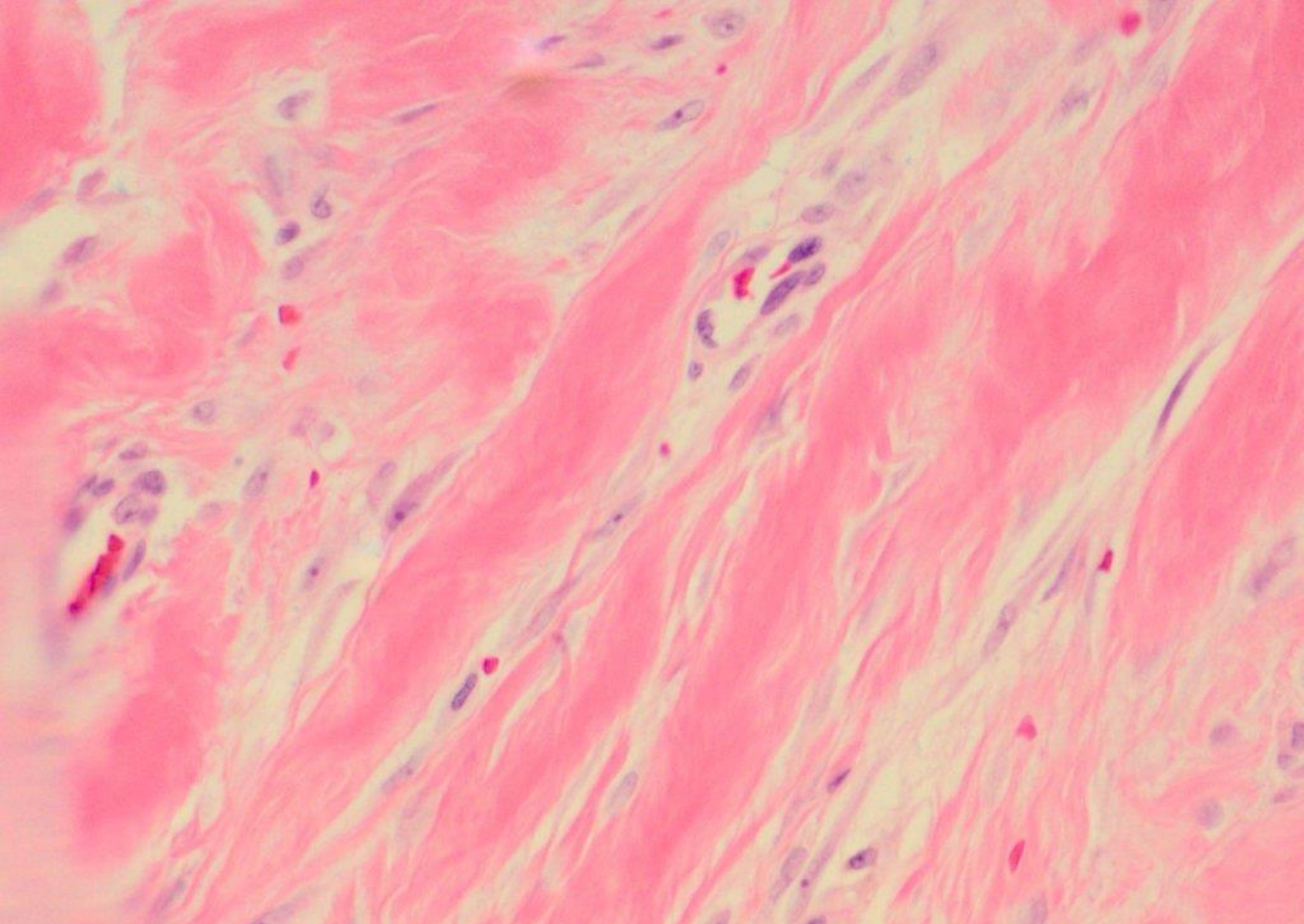












keloid